



## **Toxic Activity of *Tinospora bakis* (Irg al-hagar) Roots in Wistar Albino Rats**

**Hayat M. Farah<sup>1\*</sup>, Hassan E. Khalid<sup>2</sup>, Abdelrahim M. El Hussein<sup>1</sup> and Halima Mohamed Osman<sup>1</sup>**

<sup>1</sup>Central Veterinary Research Laboratory, Animal Resources Research Corporation, P.O.Box 8067 (El Amarat), Khartoum, Sudan.

<sup>2</sup>Faculty of Pharmacy, University of Khartoum, Khartoum, Sudan.

### **Authors' contributions**

*This work was carried out in collaboration between all authors. Author HMF designed the study, wrote the protocol, managed the literature searches and wrote the first draft of the manuscript. Authors HEK and AMEH guided the team work. Author HMO managed the histopathological study. All authors read and approved the final manuscript.*

### **Article Information**

DOI: 10.9734/EJMP/2018/42694

#### Editor(s):

- (1) Dr. Shanfa Lu, Professor, Institute of Medicinal Plant Development, Chinese Academy of Medical Sciences & Peking Union Medical College, China.  
(2) Dr. Marcello Iriti, Professor, Plant Biology and Pathology, Department of Agricultural and Environmental Sciences, Milan State University, Italy.

#### Reviewers:

- (1) Roselena Silvestri Schuh, Federal University of Rio Grande do Sul, Brazil.  
(2) Matthewos Eshete, Mississippi Valley State University (MVSU), USA.  
(3) Daniela Hanganu, "Iuliu Hatieganu" University of Medicine and Pharmacy, Romania.  
Complete Peer review History: <http://www.sdiarticle3.com/review-history/42694>

**Original Research Article**

**Received 09 May 2018**  
**Accepted 24 July 2018**  
**Published 09 February 2019**

### **ABSTRACT**

**Aim:** This study aims to evaluate the toxic effect of *Tinospora bakis* roots on body weight, hematology, biochemistry and histopathology on rats.

**Methodology:** Twenty four male Wistar albino rats were divided into four groups, each of 6. For sub chronic toxicity, the aqueous extract was administered orally at a dose of 50, 500 and 2000 mg/ kg -for four weeks- to group 2, 3 and 4, respectively whereas Group 1 was kept as a control. Clinical signs and mortality were observed daily. The weights of the animals were recorded weekly. Blood samples were collected for hematology and biochemistry analysis. Specimens of liver and kidney were kept in 10% formalin for histopathology.

**Results:** The results revealed that all animals in the four groups survived, and no mortality was recorded. The body weights of the animals increased in group 2 and 3, decreased in group 4. The extract had no adverse effects on hematology, biochemistry and histology of rats at doses of 50

\*Corresponding author: E-mail: hayatmahgoub@yahoo.com;

and 500 mg/ kg, but caused significant alteration at dose 2000 mg/kg. White blood cells (WBCs) were significantly ( $P<0.05$ ) increased; Red blood cells (RBCs), Hemoglobin (Hb) and Packed cell volume (PCV) were significantly ( $P<0.05$ ) decreased. Total protein and albumin were significantly ( $P< 0.05$ ) decreased whereas Urea, creatinine, Alanin Transaminase (ALT), Asparate Transaminase (AST) and Alkaline phosphatase were significantly elevated. These findings correlated with histopathological changes on liver and kidney.

**Conclusion:** The low doses of *T. bakis* aqueous extract were not toxic, but the high dose cause hepato-renal toxicity.

**Keywords:** *Tinospora bakis*; aqueous extract; toxicity; rats.

## 1. INTRODUCTION

*Tinospora bakis* (A.Rich) Miers in Hook. Niger. Fl.: 215 (1849) belongs to the family Menispermaceae. It is known in Sudan as Irg al - hagar. It is found at low plains and distributed in West and Central Africa [1].

Many plants contain chemical constituents which are used for different medical purposes. However, over dosage of plant products containing medical compounds may cause toxic effects when introduced into the body [2]. The toxic phytochemicals produced by plants include alkaloids, sulphur, phenol, tannin, proteins and enzyme inhibitors [3]. Toxins have direct and indirect mechanisms of actions on the target organs (liver, kidney, brain, lung and intestine). The mechanisms of actions include direct and indirect damage of tissue, effect on function and genetic defect [4].

In view of the various medical uses and pharmaceutical results of *Tinospora bakis*, preliminary screening of the plant for *in vivo* toxicity is needed. Palamtine isoquinoline alkaloid was isolated from the plant [5]. The woody part of the root of *Tnospora bakis* (A. Rich) Miers has a high character in West Africa as a diuretic and febrifuge [6]. In addition, the root is used against jaundice, hematuria, bilious fever and yellow fever, malaria and schistosomiasis. Externally, the decoction is applied against various skin problems. The leaves are similarly used as diuretic and tonic. The aqueous extract of the root containing the alkaloid fraction showed moderate activity against *Plasmodium falciparum* [7]. Syrup of the aqueous root extract induced a significant increase of the biliary secretion in rats [8]. Columbine, in small doses, was found to increase the bile, stomach and intestine secretion; in high doses it produced greasy degeneration of the liver. Palamtine showed a stronger antipyretic effect in rabbits [9]. A

lyophilized aqueous extract of *T. bakis* at concentration of 1-4 mg/ml showed *in vitro* hepato-protective activity after treatment with  $CCl_4$  [10]. In mice, the aqueous extract of the root administered either intra peritoneal or subcutaneously showed  $LD_{50}$  of 360 and 425 mg/ kg, respectively.

On the other hand, intra peritoneal administration of *T. bakis* methanolic extract to rats at a dose of 100 mg/ kg was toxic [11]. *In vitro* study of the plant caused cytotoxicity on lymphoblast cells at concentration of 10 mg/ ml [12].

Other species of *Tinospora*, such as *T. tomentosa* aqueous and methanolic extracts were found to be non toxic in mice and rats at doses up to 3.5 g/ kg [13]. *Tinospora rumphii* is a folkloric medicinal plant that is widely distributed in Asia and Africa. It has been used to treat many diseases including jaundice which is a manifestation of liver damage [14].

*Tinospora bakis*, *T. cordifolia*, *T. crispa*, *T. sinensis*, *T. smilacina*, and *T. sagittata* have been reported to possess significant immunomodulatory effect [15].

In Sudan, the macerated roots of *T. bakis* are used for headache in folk medicine [4]. The plant extract investigated against *Plasmodium falciparum* [16], *Madurella mycetomatis* [17]. Furthermore, *T. bakis* was evaluated for trypanocidal [11], antitheilerial [12] and antidiabetic activity [18].

The objective of plant toxicity test is to clarify the toxic effects of the plant. The toxicity of *T. bakis* roots extract is necessary since this has not been previously done in depth.

## 2. MATERIALS AND METHODS

### 2.1 Plant Collection

The roots of *T. bakis* were collected from Ingassana hill in East- south of The Sudan. The

plant was identified and authenticated by a botanist at the Medicinal and Aromatic Plants Research Institute, Khartoum, Sudan. The voucher specimen has been deposited in the herbarium museum of the Institute. The plant air-dried in the shade, coarsely powdered and kept in polythene bags at room temperature.

## 2.2 Animals

Clinically normal, twenty four male Wistar albino rats, 4-5 weeks of age, weighing (114-117 g) were brought from the Medicinal and Aromatic Plants Research Institute, Khartoum, Sudan. The animals were kept in metal cages to adapt for one week. The rats were fed with a standard diet which is manufactured commercially for poultry (Layers). Feed and water were provided *ad libitum*. This work was carried out according to the international regulations for the use of laboratory animals. Principles of laboratory animal care" (NIH Publication No. 85-23, revised 1985) were followed, as well as national laws were applicable.

## 2.3 Preparation of Plant Extract

The plant extract was prepared as described previously [19]. Hot distilled water (500 ml) was added to 100 g of the coarsely powdered plant roots and left to cool down with continuous stirring at room temperature. The extract was then filtered through Whatman No. 1 filter paper, and then transferred to the freeze-dryer (Trivac, U.S.A.). The yield percentage of the extract was 7.89%.

The required weight of the extract for each group was calculated according to the dose, dissolved in 6 ml of distilled water.

## 2.4 Experimental Designs

Twenty four male Wistar albino rats were divided into four groups, each of 6 rats. Group 2, 3 and 4 were used for testing of sub chronic toxicity, and group 1 was kept as a control. The extract was given at one of the fixed dose level (50, 500 and 2000 mg/kg) as low, intermediate and high level.

### 2.4.1 Screening of the aqueous extract of *T. bakis* roots for toxicity

The volume of the extract given to each animal based on the body weight. The aqueous extract of the plant was administered orally to the rats in group 1, 2 and 3 at doses of 50, 500 and 2000 mg/ kg/ day, respectively for four weeks; keeping group 1 as a control.

Clinical signs of toxicity and/or mortality were observed daily. The weights of the rats were recorded at the day of dosing, at weekly intervals thereafter, and at the time of death or when the animals were euthanized.

## 2.5 Blood Collection for Hematological and Biochemical Analysis

Blood samples were collected weekly-starting from week zero (Control) - from the orbital sinus of rat's eye - in Ethylene Diamine Tetra acetic acid (EDTA) and plain vacutainers, for hematological and biochemical tests, respectively. Sysmex Haematology System KN-21N/Germany and Sysmex Biochemistry System / Germany) instruments were used for analysis. The procedures were carried out as described in the manual of the automated machines.

## 2.6 Pathological Examination

Rats in group 1, 2, 3 and 4 were euthanized at the end of the experiment. Specimens of normal and abnormal liver and kidney were fixed in 10% neutral buffered formalin and processed for histopathological examination.

## 2.7 Statistical Analysis

The data collected during the study were analyzed using the computer program SPSS version 20. The statistical analysis was done using One Way ANOVA, followed by Duncan multiple comparison test. The data are expressed as mean  $\pm$ SD. The results with  $P < 0.05$  were considered significant.

## 3. RESULTS

### 3.1 Effect of the Extract on Mortality and Body Weight

There was no mortality recorded even at the highest dose (2000 mg/kg) after oral administration of the extract.

The aqueous extract of *T. bakis* roots was well tolerated by the animals after oral administration of the doses 50, 500 and 2000 mg/ kg to group 2, 3 and 4, respectively.

The effect of the extract on body weights of rats was shown (Fig. 1). The extract significantly ( $P < 0.05$ ) increased the bodyweights of rats in group 1, 2 and 3; decreased in group 4.

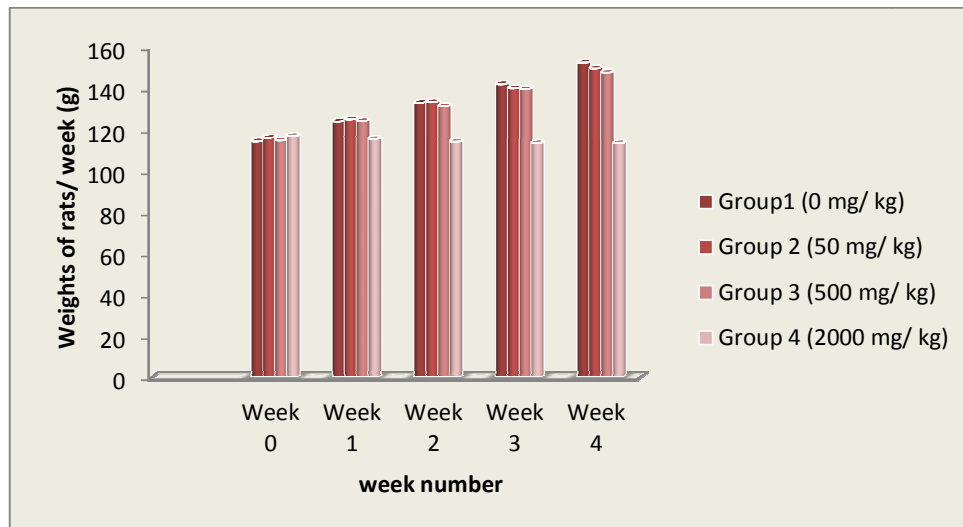


Fig. 1. Effect of aqueous extract of *T. bakis* roots at different doses on bodyweight of rats per week

### 3.2 Effect of the Extract on Hematological and Biochemical Parameters

The plant extract altered the haematology and biochemistry of rats in group 4 only. The haematological changes on blood of rats administered orally aqueous extract of *T. bakis* were summarized (Table 1). WBCs, RBCs, Hb and PCV were not affected in group 2

and 3, but significantly ( $P < 0.05$ ) changed in group 4.

The toxicological effects of the extract on the biochemical parameters were presented (Table 2). Oral administration of the aqueous extract at doses of 50 mg/ kg and 500 mg/ kg had no effect. However, the dose of 2000 mg/ kg was significantly ( $P < 0.05$ ) altered all the parameters.

Table 1. Hematological changes on the blood of rats given aqueous extract of *Tinospora bakis*

Group no.	Week no.	Dose (mg/kg)	WBCs ( $\times 10^3/\text{mm}^3$ )	RBCs ( $\times 10^6/\text{mm}^3$ )	Hb (g/dl)	PCV (%)
1	0	0	5.90 $\pm$ 0.14	6.32 $\pm$ 0.08	11.68 $\pm$ 0.19	37.50 $\pm$ 0.40
	1		5.90 $\pm$ 0.09	6.35 $\pm$ 1.05	11.72 $\pm$ 0.21	37.53 $\pm$ 0.39
	2		5.92 $\pm$ 0.80	6.35 $\pm$ 0.08	11.72 $\pm$ 0.21	37.55 $\pm$ 0.39
	3		5.93 $\pm$ 0.10	6.38 $\pm$ 0.08	11.73 $\pm$ 0.15	37.57 $\pm$ 0.42
	4		5.91 $\pm$ 0.15	6.37 $\pm$ 0.08	11.73 $\pm$ 0.15	37.57 $\pm$ 0.43
2	0	50	6.77 $\pm$ 0.10	6.95 $\pm$ 0.10	11.93 $\pm$ 0.14	38.13 $\pm$ 0.26
	1		6.77 $\pm$ 0.10	6.97 $\pm$ 0.05	11.95 $\pm$ 0.12	38.18 $\pm$ 0.26
	2		6.83 $\pm$ 0.08	6.93 $\pm$ 0.08	11.95 $\pm$ 0.12	38.18 $\pm$ 0.26
	3		6.85 $\pm$ 0.08	6.93 $\pm$ 0.05	11.93 $\pm$ 0.14	38.12 $\pm$ 0.26
	4		6.85 $\pm$ 0.08	6.93 $\pm$ 0.10	11.93 $\pm$ 0.14	38.12 $\pm$ 0.26
3	0	500	7.05 $\pm$ 0.19	6.80 $\pm$ 0.14	11.82 $\pm$ 0.17	38.02 $\pm$ 0.17
	1		7.45 $\pm$ 0.76	6.82 $\pm$ 0.15	11.80 $\pm$ 0.21	38.00 $\pm$ 0.17
	2		7.12 $\pm$ 0.15	6.82 $\pm$ 0.19	11.77 $\pm$ 0.23	38.00 $\pm$ 0.17
	3		7.12 $\pm$ 0.15	6.77 $\pm$ 0.20	11.75 $\pm$ 0.26	37.85 $\pm$ 0.20
	4		7.15 $\pm$ 0.14	6.68 $\pm$ 0.16	11.58 $\pm$ 0.23	37.53 $\pm$ 0.22
4	0	2000	6.65 $\pm$ 0.19	7.05 $\pm$ 0.24	12.02 $\pm$ 0.25	38.45 $\pm$ 0.33
	1		8.95 $\pm$ 0.24*	4.93 $\pm$ 0.44*	10.77 $\pm$ 0.41*	36.23 $\pm$ 0.31*
	2		9.00 $\pm$ 0.22*	4.72 $\pm$ 0.38*	10.50 $\pm$ 0.41*	36.00 $\pm$ 0.24*
	3		9.06 $\pm$ 0.23*	4.70 $\pm$ 0.46*	10.48 $\pm$ 0.40*	36.00 $\pm$ 0.28*
	4		9.06 $\pm$ 0.21*	4.71 $\pm$ 0.42*	10.48 $\pm$ 0.40*	36.00 $\pm$ 0.28*

The data presented as Mean  $\pm$  SD, \* $P < 0.05$  is significantly different from the control,  $n=6$

**Table 2. Biochemical changes on blood of rats after administration of aqueous extract of *Tinospora bakis***

Group no.	Week no.	Dose (mg/kg)	Total protein (g/dl)	Albumin (g/dl)	Billirubin	Urea (mg/dl)	Creatinine (mg/dl)	ALT (IU/L)	AST (IU/L)	ALP (IU/ L)
1	0	0	6.35±0.20	3.53±0.16	0.13±0.05	14.67±0.26	0.53±0.05	13.00±0.89	18.33±0.82	53.00±1.41
	1		6.39±0.18	3.55±0.31	0.13±0.05	14.68±0.23	0.53±0.05	13.05±0.90	18.33±0.82	53.00±1.41
	2		6.46±0.19	3.65±0.26	0.10±0.00	14.68±0.32	0.53±0.05	13.05±0.90	18.42±0.83	53.00±1.67
	3		6.47±0.25	3.73±0.23	0.10±0.00	14.70±0.28	0.58±0.04	13.08±0.94	18.42±0.83	53.17±1.17
	4		6.67±0.16	3.80±0.17	0.10±0.00	14.70±0.26	0.53±0.05	13.10±0.85	18.43±0.80	53.17±1.17
2	0	50	6.35±0.19	3.70±0.09	0.15±0.05	14.52±0.15	0.50±0.00	13.60±0.14	18.60±0.26	53.83±1.72
	1		6.47±0.18	3.70±0.09	0.15±0.05	14.52±0.15	0.50±0.00	13.60±0.14	18.62±0.24	53.83±1.72
	2		6.47±0.18	3.72±0.08	0.15±0.05	14.53±0.16	0.50±0.00	13.62±0.12	18.62±0.24	53.83±1.33
	3		6.43±0.16	3.72±0.08	0.15±0.05	14.53±0.16	0.50±0.00	13.62±0.12	18.65±0.23	53.83±1.17
	4		6.43±0.16	3.70±0.08	0.15±0.05	14.56±0.14	0.50±0.00	13.62±0.12	18.65±0.23	53.83±1.17
3	0	500	6.65±0.19	3.80±0.09	0.12±0.04	14.50±0.66	0.48±0.04	14.00±0.24	18.90±0.23	53.83±1.17
	1		6.65±0.19	3.80±0.06	0.12±0.04	14.50±0.66	0.48±0.04	14.03±0.27	18.95±0.18	53.83±0.89
	2		6.63±0.20	3.83±0.05	0.13±0.05	14.55±0.61	0.50±0.06	14.07±0.28	18.95±0.16	53.83±0.89
	3		6.60±0.21	3.83±0.05	0.13±0.05	14.58±0.61	0.55±0.08	14.07±0.28	18.95±0.16	54.00±1.26
	4		6.60±0.21	3.80±0.00	0.13±0.05	14.43±0.87	0.55±0.08	14.08±0.21	18.93±0.18	54.00±1.26
4	0	2000	6.72±0.15	3.85±0.08	0.10±0.00	14.30±0.23	0.45±0.05	13.90±0.17	18.75±0.10	53.67±0.82
	1		5.45±0.19*	3.05±0.12*	0.57±0.05*	17.45±0.34*	0.68±0.08*	15.90±0.28*	21.47±0.26*	56.50±1.05*
	2		5.00±0.13*	2.00±0.08*	0.60±0.00*	17.97±0.36*	0.75±0.05*	16.13±0.28*	21.48±0.23*	57.00±1.26*
	3		5.00±0.16*	2.00±0.06*	0.60±0.04*	17.99±0.38*	0.76±0.06*	16.15±0.30*	21.50±0.20*	57.20±1.30*
	4		4.90±0.18*	2.00±0.07*	0.61±0.00*	17.98±0.40*	0.77±0.06*	16.20±0.34*	21.87±0.25*	57.50±1.32*

The data expressed as Mean ± SD, \*P < 0.05 is significantly different from the control, n= 6

### 3.3 Histopathological Changes

Necropsy of rats in group 1, 2, 3 showed normal livers and kidneys. Though, the extract caused histopathological changes in liver and kidney (Group 4). The liver characterized by vesicular nuclei and accumulation of cytoplasm at the boundaries of hepatocytes (Fig. 2B), compared with the control (Fig. 2A). The kidney revealed dilated and segmented glomerular tuft (Fig. 3B) referring to the control (Fig. 3A).

### 4. DISCUSSION

There were no changes on the animals' behavior and/or mortality recorded after oral administration of repeated doses at 50, 500 and 2000 mg/ kg of the aqueous extract of *T. bakis* roots. This result in agreement with the findings mentioned that

different doses of the extract were not fatal up to a dose of 2000 mg/ kg [18]. On the other hand, the dose 2000 mg/ kg was toxic but not fatal. This result disagree with previous study reported that the aqueous and methanolic extracts of *T. tomentosa* were found to be non toxic in mice and rats at doses up to 3.5 g/ kg [9]. The variation could be to the different plant species.

Body weight changes may reflect the general health status of animals [20]. In the current work, the body weight gain in group 2 and 3 suggest that the extract did not interfere with the normal body metabolism of the animal as the increment in food and water intake is synonymous to an increase in body weight. This indicates that the extract of *T. bakis* did not have general toxic effects and influence on animal food intake at doses of 50 and 500 mg/ kg. The findings were

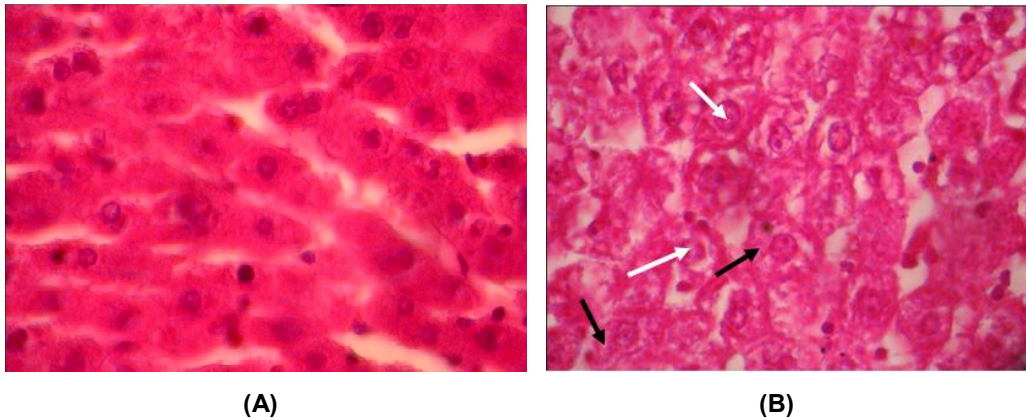


Fig. 2. Section of rat liver: (A) Normal control (group 1). (B) After oral administration of aqueous extract of *T. bakis* at a dose of 2000 mg/ kg (group 4) showed vesicular nuclei (white arrows) and accumulation of cytoplasm at the boundaries of hepatocytes (black arrows), H&E ( $\times 40$ )

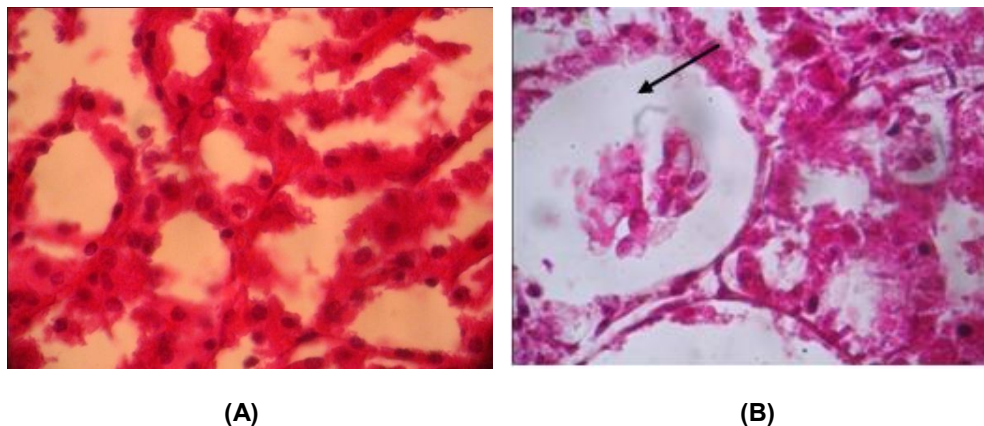


Fig. 3. Section of rat kidney: (A) Normal control (group 1). (B) Dosing of 2000 mg/ kg aqueous extract of *T. bakis* (group 4) dilated and segmented glomerular tuft (black arrow), H&E ( $\times 40$ )

supported by previous results in which the aqueous extract of the plant improved the body weight of diabetic rats at a dose of 400 mg/kg/day [18]. However, decrease in bodyweight (group 4) indicated abnormality or toxicity which influenced food consumption and metabolism.

The assessment of blood hematology and clinical biochemistry provides an insight to possible damage caused by the extract in the hepatic and renal functions. In toxicity studies, evaluation of liver and kidney functions is germane because both organs are essential for the survival of an organism [21], Hematological and biochemical changes are indicators of toxicities [22]. The doses of 50 and 500 mg/kg had no toxic effects on both parameters as well as the histological findings. This finding disagree with previous result exhibited that intra peritoneal administration of *T. bakis* methanolic extract to rats at a dose of 100 mg/ kg was toxic; causing decrease in hematological values and an increase in serum enzymes [11]. This could be due to the variation in the solvent used and the route of administration.

Increase of WBCs in group 4 could be attributed to the combined effects of physiological and chemical factors in the metabolic system of animals [23]. The mechanism of action of WBCs and its component are defensive against foreign substances. The alteration in RBCs and Hb may be due to defective hematopoiesis inhibited erythropoiesis or increase in destruction of red blood cells [24,25] which could cause anaemia.

The biochemical changes are biomarker of abnormality or toxicity. Evaluation of total protein gives an estimation of the nutritional status and diagnostic measurement of liver and kidney diseases [26]. Reduction in total protein and albumin is an indicator of impaired hepato cellular function [27]. The observed increase ( $P < 0.05$ ) of serum urea and creatinine in group 4 suggest renal malfunction [28]. Transaminases (ALT and AST) and Alkaline phosphatase are sensitive enzymes used to assess the severity of liver damage [29]. Primary and secondary hepatic diseases can cause elevation of both ALT and AST [30]. The increment in the activities of transaminases indicates that the plant may induce hepatic parenchyma injury, hepatic dysfunction and leakage of these enzymes from liver cytosol to the blood stream [31,32]. Overall, the biochemical changes were correlated with

the histopathological findings on the liver and kidney.

## 5. CONCLUSION

The results revealed that the low doses of the aqueous extract of *T. bakis* roots were not toxic, but the highest dose may cause hepato renal toxicity. Further research is recommended for isolation, structural determination and identification of the toxic compounds; and the mode of action of the plant *T. bakis*.

## CONSENT

It is not applicable.

## ETHICAL APPROVAL

All authors hereby declare that "Principles of laboratory animal care" (NIH Publication No. 85-23, revised 1985) were followed, as well as national laws were applicable. The protocol for the use of laboratory animals in this study was approved by the Ethical Approval No. EA /0019/2018, The Sudan Veterinary Council, Ministry of Cabinet, Republic of The Sudan.

## ACKNOWLEDGEMENTS

The authors acknowledged Central Veterinary Research laboratory for permission to publish this article. Our thanks extended to Dr. Hala Elrayah at the Department of Biochemistry, Nutrition, Toxicology and Pharmacology for performance of statistical analysis.

## COMPETING INTERESTS

Authors have declared that no competing interests exist.

## REFERENCES

1. El Ghazali GEB, Abdalla WE, Khalid HE, Khalafalla MM, Hamad AA. *Tinospora bakis* (A. Rich) Miers In: Medicinal Plants of The Sudan, part V. Medicinal Plants of the Ingassana area, Sudan. Currency Printing Press. 2003;101-102.
2. Farah HF, Elamin TH, El Hussein AM, Khalid HE. Assessment of antitheilerial activity of *Kigelia africana* fruits against *Theileria lestoquardi*. Eur J Med Plants. 2015;5(1):101-108. ISSN: 2231-2927.

3. Maiga A, Diallo D, Fane S, Sango K, Paulsen BS, Cisse B. A survey of toxic plants on the market in the district of Bamako, Mali: Traditional knowledge compared with literature search of modern pharmacology and toxicology. *J Ethnopharm.* 2005;96:183-193.
4. Chandra SJ, Sandhya S, Vinod KR, David B, Sudhakar K, chaitanga R, Plant toxins harmful effects. *Hygeia J Drugs Med.* 2012;4(1):70—90.  
Available:www.hygeiajournal.com
5. Oliver- Beaver B. Selecting local drug plants in Nigeria. Botanical and chemical relationship in three families. *QJ Crude Drug Res.* 1968;82:1194.
6. Oyen LPA. *Tinospora bakis* (A. Rich) Miers [Internet] Record from Prota 4 U. Schelzer, GH and Gurib – Fakim A (editors). PROTA (Plant Resources of Tropical Africa), Wageningen, Netherlands; 2008.  
Available:http://www.prota4u.org/search.asp
7. Quattara Y, Sanon S, Traore H, Mahino V, Azas N, Sawadogo L. Antimalarial activity of *Swartzia madagascariensis desis* (Leguminosae), *Combretum glutinosum* guill and pier (Combetaceae) and *Tinospora bakis* (Menispermaceae), Burkina Faso medicinal plants. *Afr J Trad Complement Altern Med.* 2006;3(1):75-81.
8. Diallo SAM, Gueye M, Sarr M, Diaye AKN, Diye MND, Faye B. Effect of mechanism of action of *T. bakis* roots on biliary secretion using *in vivo* models. *Dakar Med.* 1999; 44:211-214.
9. Zafinindra LR, Diatta W, Diaye AM, Nongonierma R, Faye B, Bassene E. Antipyretic effect of aqueous and alkaloid extract of *Tinospora bakis* (Miers) in rabbits. *Dakar Med.* 2003;48(1):29-33.  
Available:http://www.pubmed.gov. PMID: 1577664.
10. Diallo -Sall A, Niang- Ndiaye M, Ndiay AK, Dieng C, Faye B. Hepato-protective effect of a plant from the Seneglese pharmacopoeia using an *in vitro* model. *Dakar Med.* 1997;42(1):15-18.
11. El Hassan IBME. Trypanocidal efficacy of *Erythrina abyssinica*, *Tinospora bakis* and *Polygala erioptera* against *Trypanosoma evansi*. M. V. SC. Thesis, U of K, Khartoum, Sudan; 2008.
12. Farah HM, El Hussein AM, El amin T H, Khalid HE. *In vitro* effect of aqueous extract of *Tinospora bakis* roots on *Theileria lestoquardi*. *Topcls J Herb Med.* 2013;2(1):1-6.  
Available:http://www.topclsglobaljournalsmedicinalPlants.org
13. Devbhuti D, Gupta JK, Devbhuti P, Bose A. Phytochemical and acute toxicity of *Tinospora tomentosa* Miers. *Acta Poloniae Pharmaceutica- Drug Res.* 2009;66(1):89-92.  
ISSN: 0001-6837.
14. Tan RS, Bajo LM. Modulation of *Tinospora rumphii* and zinc salt on DNA damage in Quinoline –induced genotoxicity and hepatotoxicity in male albino mice. *Adv Toxicol.* 2014;62:1-9.  
DOI: 10.1155/2014/201762
15. Haque MA, Jantan I, Bukhari SNA. *Tinospora* spp.: An overview of their modulatory effects on the immune system. *J Ethnopharm.* 2017;207:67-85.  
Available:http://doi.org/10.1016/j.jep.2017.06.013
16. Goda KMAA. Phytochemical and pharmacological studies of selected medicinal plants with emphasis on *polygonum glabrum*. PhD thesis, Pharmacol, U of K; 2004.
17. AbdElGaffar S, Khalid SA. An *in vitro* evaluation of *Tinospora bakis* and *Curcuma longa* against *Madurella mycetomatis*. Conference paper: 63<sup>rd</sup> international Conference of the Society of Medicinal Plants and Natural product Research, held at Budapest, Hungary; 2015.
18. Alamin MA, Yagi AI, Yagi SM. Evaluation of antidiabetic activity of plants used in Western Sudan. *Asian J Trop Biomed.* 2015;5(5):395-402.  
Available:http://doi.org/10.1016/S2221-1691(15)30375-0
19. Harborne JB, Editor. *Phytochemical methods*. 2<sup>nd</sup> Ed., Chapman and Hall Ltd., London; 1984.
20. El Hilaly J, Israili ZH, Iyousi B. Acute and chronic toxicological studies of *Ajuga iva* in experimental animals. *J Ethnopharm.* 2004;91(1):43-50.
21. Olorunnisla OS, Bradley G, Afolayan AJ. Acute and subchronic toxicity studies of methanolic extract of *Tulbaghia violacea* rhizomes in Wistar rats. *Afr J Biotech.* 2012;2:14934-14940.
22. Debebe M, Afework M, Makonnen E, Debella A, Geleta B, Gameda M. Evaluation of biochemical, haematological and histopathological parameters of sub



- chronic administration of ethanol extract of *Albizia gummifera* in albino wistar rats. *J Clin Toxicol.* 2017;7(1):337-345.  
DOI: 10.4172/2161-0495.1000337
23. Nyarko AK, Okine LKN, Wedzi RK, Addo PA, Ofosuhne M. Sub chronic toxicity of the antidiabetic herbal preparation ADD 199 in the rat: Absence of organ toxicity and modulation of cytochrome P450. *J Ethnopharm.* 2015;97(2):319-325.  
Available:<http://hdl.handle.net/123456789/3231>
  24. Keinänen M, Kunutila S, Bloomfield CD, Elonen E, de la Chapelle A. The proportion of mitosis in different cell lineages changes during short-term culture of normal human bone marrow. *Blood.* 1986;67:1244-1243.
  25. Selmanoglu G, Barlas N, Songür S, Kockaya EA. Carbendazim induced haematological, biochemical and histopathological changes to the liver and kidney of male rats. *Hum Exp Toxicol.* 2001;20:625-630.
  26. Ozer J, Ratner M, Shaw M, Baily W, Schomaker S. The current state of serum biomarkers of hepatotoxicity. *Toxicol.* 2008;245(3):194-205.
  27. Balogun FO, Ashafa AOT. Acute and subchronic oral toxicity evaluation of aqueous extract of *Dicoma anomala* Sond. in Wistar albino rats. *Evi Complement Alt Med.* 2016;1-11. ID: 3509323.  
Available:<http://dx.doi.org/10.1155/2016/0155660713>
  28. Cheesbrough M. Medical laboratory manual for tropical countries. Microbiology Tropical Health Technology/ Butterworth Scientific Publications, Boston. 1991;167-214.  
Available:<http://www.isorjournals.org>
  29. Ramaiah SK. Preclinical safety assessment: Current gaps, challenges and approaches in identifying translatable biomarkers of drug-induced liver injury. *Clin Lab Med.* 2011;31(1):161-172.
  30. Wuruchekke AU, Anthony AE, Obiolah W. Biochemical effects on liver and kidney of rats administered aqueous extract of *Xemenia americana*. *Afr J Biotech.* 2008;7:2777-2780.  
ISSN: 1684-5315.
  31. El-Demerdash FM, Yousef MI, El-Naga NI. Biochemical study on the hypoglycemic effects of onion and garlic on alloxan-induced diabetic rats. *Food Chem Toxicol.* 2005;43:57-63.
  32. Abdelmajeed NA. Oxidative tissue damage induced by citalopramin in rat different organs. *Res J Med Med Sci.* 2009;4:580-586.

© 2018 Farah et al.; This is an Open Access article distributed under the terms of the Creative Commons Attribution License (<http://creativecommons.org/licenses/by/4.0>), which permits unrestricted use, distribution, and reproduction in any medium, provided the original work is properly cited.

Peer-review history:  
The peer review history for this paper can be accessed here:  
<http://www.sdiarticle3.com/review-history/42694>