



Treatment of Grade 3 Fatty Liver by the Principles of Persian Medicine: A Case Report

Alireza Niknafs¹, Seied Amirhossein Latifi² and Mehdi Salehi^{2*}

¹Department of Persian Medicine, Traditional and Complementary Medicine Research Center of Arak University of Medical Sciences, Arak, Iran.

²Traditional and Complementary Medicine Research Center, Faculty of Medicine, Arak University of Medical Sciences, Arak, Iran.

Authors' contributions

This work was carried out in collaboration among all authors. Author AN wrote the first draft of the manuscript, performed the statistical analysis and managed the analysis of the study. Author SAL managed the analysis of the study. Author MS designed the study, wrote the protocol and managed the literature searches. All authors read and approved the final manuscript.

Article Information

DOI: 10.9734/JPRI/2020/v32i4531086

Editor(s):

(1) Dr. Rafik Karaman, Al-Quds University, Palestine.

Reviewers:

(1) Fatma Duksal, Konya Education and Research Hospital, Turkey.

(2) Flavia De Bittencourt, Universidade Federal Fluminense, Brasil.

Complete Peer review History: <http://www.sdiarticle4.com/review-history/64237>

Short Research Article

Received 25 October 2020

Accepted 01 January 2021

Published 30 January 2021

ABSTRACT

Introduction: Nowadays, societies have witnessed a rapid increase of Fatty Liver, which is one of the most common liver diseases worldwide, due to some changes in lifestyle and the increased obesity and metabolic syndrome.

Case presentation: in this study, the patient under research was a 41-year-old woman who was diagnosed with grade 3 fatty liver caused by the absence of a healthy diet and lifestyle. She was successfully treated using the methods of Traditional Iranian Medicine.

Discussion: Classical medicine is not able to develop a certain treatment for this disease yet. Therefore, this article has mainly concentrated on the therapeutic effects of medicinal herbs on the liver.

Conclusion: Delays in the diagnosis and treatment of fatty liver may lead to irreversibility or liver Cirrhosis, which cannot be treated using any method, but by liver transplants. However, the principles of PM (Persian Medicine) can be useful as useful in the prevention and treatment of this disease.

Keywords: Case report; fatty liver; metabolic syndrome; persian medicine.

1. INTRODUCTION

Fatty Liver, which is one of the most common liver diseases worldwide, usually emerges due to lipid aggregation (mostly triglyceride) in hepatocytes. Fat exists in the liver naturally, but if it surpasses 5 - 10% of the liver's total weight, it can result in fatty liver. This disease should be considered serious due to the destruction of hepatocytes, making it possibly irreversible if proper diagnosis and treatment are delayed. Moreover, it may even result in Liver Cirrhosis, which is incurable, except by liver transplant [1].

This disease is the most common disorder in industrial societies according to its direct connection with lifestyle. Also, it is equally common among men and women. Early diagnosis and proper treatment of this disease can prevent the critical complications caused by that and also make it reversible. In this regard, the most recognized clinical symptom of fatty liver is the lack of symptoms, making it impossible to be detected, except via ultrasonography. Accordingly, the other possible symptoms include tiredness, nausea, vomiting, lack of appetite, pain in the liver area, itching, changes in the urine and stool color, and the increased liver enzymes [2].

Ultrasonography has proven as the first step in the diagnosis of fatty liver because of its high accessibility and cost-effectiveness, as well as high sensitivity in detection. Accordingly, liver biopsy has been proven to be the most accurate method of the diagnosis and assessment of liver damage [3].

Classical medicine has not determined a certain verified method of treatment for fatty liver yet. In this regard, the most of the current methods are only capable of reducing the risk of factors [4]. PM can not only offer an improvement of lifestyle but can also present several treatments.

2. CASE PRESENTATION

The patient was a 41-year-old woman, mother of three children, relatively obese, with a weight of 97 kg, a height of 162 cm, and pain under right side ribs. She referred to a PM clinic on March 30, 2018, reporting a sense of heaviness, hasty tiredness, feeling of warmth throughout her body, general weakness throughout her body, dyspnea

followed by stress, and excessive sweating after physical movement mostly in her head and neck area. She suffered no constipation but mentioned bloating, belching, and dyspepsia. She also had PND, (Paroxysmal nocturnal dyspnea) infraorbital edema, occasional headaches, and feelings of dizziness.

The other reported symptoms were as follows: feelings of weakness, warmth, and occasional muscle spasm in limbs, especially on the plantar surface of the feet. Notably, urine color was natural. However, periods were disordered despite having normal density, amount, and color of the menstrual blood. She had no records of special medications or any cardiovascular problems. In addition, she had three successful attempts at giving birth by cesarian section. Also, blood pressure was 120/80 mmHg and other vital signs were normal. She had accidentally noticed grade 1 fatty liver via ultrasonography on July 30, 2018, but ignored it and refused to conform proper lifestyle instructions, while she was disorderly eating, consuming a high amount of junk foods, and habitually drinking ice-cold water.

In her first admission session, a diet consisting of a vegan soup with oat, carrots, parsley, coriander, and condiments such as salt and turmeric, was prescribed for the patient. Daily exercise and drinking herbal tea, which contained thyme, jujube, anise, chamomile, celery seeds, and licorice, were also suggested 3 times per day as well as Rheum Officinale (Chinese rhubarb) capsules twice a day for 40 days.

After 4 months – during which there had been no change in neither her exercising habits nor weight – on her second admission (August 29, 2018), the patient was generally feeling better and experiencing less stomachache, so the medications were repeated. Afterward, 35 days later, during the third admission session, another ultrasonography report was prescribed for the patient, which indicated normal liver parenchyma proportions and the absence of fatty liver. Moreover, the diameter of the liver's interior was normal and she was feeling generally well enough to stop the medications (Fig. 2). Two and a half months later (November 22, 2018), during a phone call with the patient, she stated that she was feeling completely good and had no complaints.

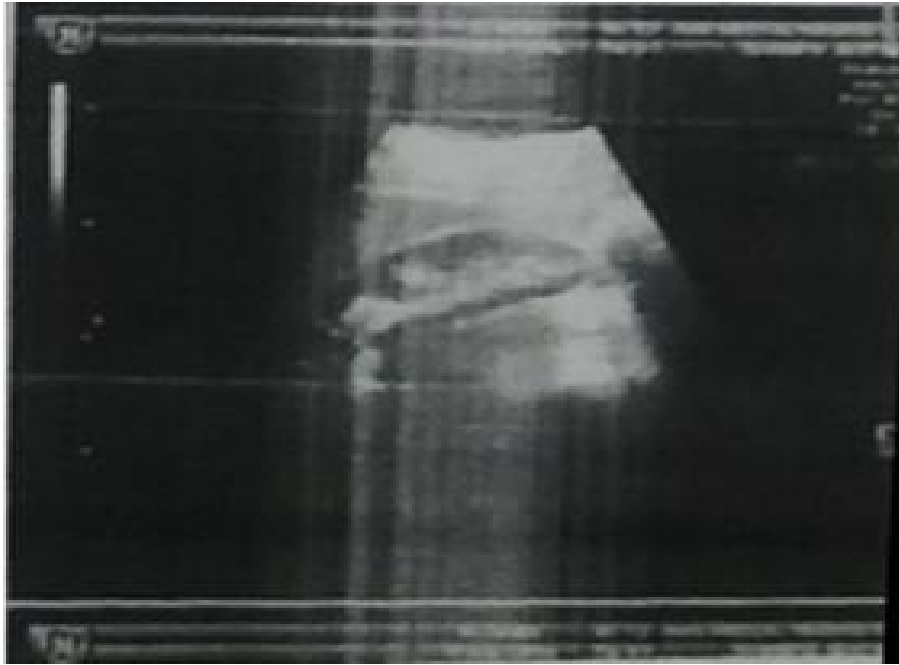


Fig. 1. The first ultrasonography reports indicated that her liver had surpassed the costal ribs by 17 mm as well as showing an excessive increase in parenchyma (grade 3 fatty liver). Moreover, normal portal vein, gallbladder, biliary ducts, spleen and kidneys were also reported

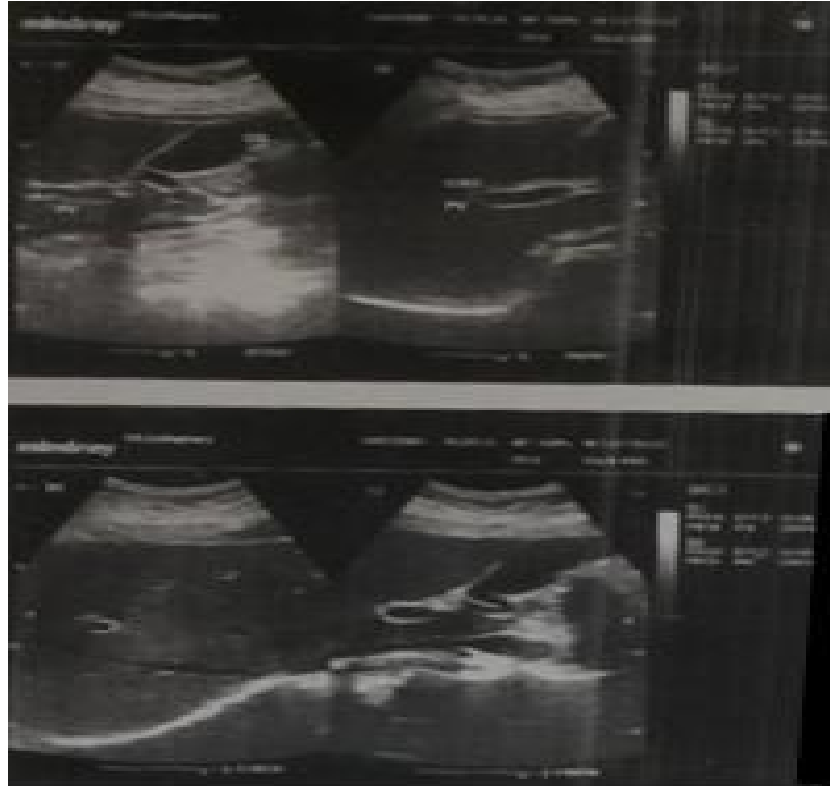

Fig. 2. The diameter of the liver's interior

Table 1. Indicates other para-clinictest results

Test	Result	Unit
FBS	83	mg/dl
Cholestrol	198	mg/dl
Triglyceride	212	mg/dl
HDL	41	mg/dl
LDL	115	mg/dl
SGPT	29	IU
SGOT	22	IU
TSH	2.78	mU/ml

*FBS=Fasting Blood Sugar, HDL=High Density Lipoprotein , LDL=Low Density Lipoprotein
 SGPT=Serum Glutamic pyruvic Transaminase, SGOT=Serum Glutamic Oxaloacetic Transaminase ,
 TSH=Thyroid Stimulating Hormone
 Mg/dl=miligram per desilitter , IU= International Unit , mU/ml=microUnits per millilitter*

3. DISCUSSION

Symptoms of alcoholic and non-alcoholic fatty liverare very similar, whereas the difference between them is detectable through a detailed assessment of the patient’s symptoms [5]. In this regard, it is noteworthy that non-alcoholic fatty liverhas a high insulin resistance and a close connection to obesity and lifestyle. It is also the major reason of liver transplant in worldwide.

More than 50% of patients with fatty liverexperience the increased liver enzymes. Ultrasonography is the first step in the diagnosis of fatty liverdue to its high accessibility, sensitivity and cost-effectiveness.

[6] In this study, diagnosis of the patient was performed through ultrasonography and the assessment of clinical symptoms and liver enzymes.

The patient refused to perform the instructions concerning eating and drinking habits. Also, she had a high amount of cold water consumption, which resulted in gastrointestinal symptoms and weakness in the stomach and gastrointestinal tract, followed by weakness and dyspepsia [7]. Aggregation of lipids in the liver can also result in coldness, moisture, enlargement, and weight increase in the liver; tension in the Glisson membrane; and pain under the ribs, which is categorized as swelling in PM. In addition, the other factors capable of causing a dysfunction in the liver and preventing it from producing normal humor include aggregation of lipid, dysfunction of liver cells, their enzymatic and biologic processes, and excessive pressure on vessels and ducts, which is referred as a liver stagnation. Therefore, in this case, aggregation of abnormal humor resulted in chronic fatigue, general

weakness, feeling of malaise, and suborbital edema.

PM considers fatty liveras a combination of cold-wet distemper, swelling, and stagnation. Accordingly, the clinical symptoms related to these conditions have been mentioned in PM books and references [8].

Classical medicine has not detected a certain verified method to treat Fatty Liver yet. Also, the most of the current treatment methods are only capable of reducing the risk of factors [9]. In this study, the patient under research was treated by the improvement of her diet and lifestyle, along with the consumption of medicinal herbs as described below:

The most important therapeutic effects of thyme (*Thymus vulgaris*) include the following: the opening of stagnation; dilution of humor; and cleansing of lungs, liver, stomach, and intestines [10].

Jujube (*Ziziphus jujuba*) can not only dilute high-consistency humor and flow diluted humor but can also produce normal humor and reduce thirst and inflammation. Furthermore, it reduces pain in the liver area and its usefulness for the hepatotoxicity effect has been proven [11].

Anise (*Pimpinella anisum*) reduces chronic fatigue, opens liver, spleen, kidney, and urinary bladder stagnations, and also reinforces the cardia of the stomach [12].

Chamomile (*Matricaria chamomilla*) decreases inflammations and swellings inside the body [13]. Celery seeds (*Apium graveoloens*) open liver, spleen, kidney, and urinary bladder stagnations.

Licorice (*Glycyrrhiza glabra*) improves gastric functions and reduces chronic fatigue, distension, dyspepsia, and inflammation in liver ducts [14].

Rhubarb (*Rheum officinale*) has pharmacological activities such as anti-inflammatory, antioxidative, so it has been widely used alone or in combination with other crude drugs for the treatment of cholestatic hepatitis from ancient times in China. The major active ingredient of the herb responsible for its hepato-protective effect is emodin, an anthraquinone [15].

4. CONCLUSION

Fatty liver, as one of the most common chronic liver diseases, is directly connected to obesity, diabetes type 2, mood disorders, chronic fatigue, sleep disorders, the unusual function of the thyroid gland, and metabolic syndrome. If diagnosis and a proper treatment of this disease are delayed, it may result in many complications such as liver dysfunction and Cirrhosis.

Classical medicine has not suggested a definite treatment for fatty liver yet. Furthermore, the chemical medications prescribed to reduce its factors often cause many complications.

In this regard, the prevention and control of this disease highly depend on the patient's lifestyle, habits, and weight control [9].

The principles and orders of TIM combined with the use of natural herbal medicine recommended for fatty liver in TIM books and resources, have been proven to be effective on the treatment and control of this disease. However, more research and statistic assessment should be still performed in a wider field of research.

CONSENT

As per international standard or university standard, patients' written consent has been collected and preserved by the author(s).

ETHICAL APPROVAL

This study was approved by the Ethical Committee at the University of Medical Sciences (Code: IR.ARAKMU.REC.1399.189).

COMPETING INTERESTS

Authors have declared that no competing interests exist.

REFERENCES

1. Kasper D, Fauci A, Hauser S, Longo D, Jameson J, Loscalzo J. Harrison's principles of internal medicine, 19e: Mcgraw-hill; 2015.
2. Rinella ME. Nonalcoholic fatty liver disease: a systematic review. *Jama*. 2015; 313(22):2263-73.
3. Han A, Byra M, Heba E, Andre MP, Erdman Jr JW, Loomba R et al. Noninvasive diagnosis of nonalcoholic fatty liver disease and quantification of liver fat with radiofrequency ultrasound data using one-dimensional convolutional neural networks. *Radiology*. 2020;295(2):342-50.
4. Lankarani KB, Alavian SM. Low carbohydrate rather than low fat is more important in the dietary management of nonalcoholic steatohepatitis. *Gastroenterology*. 2015;149(7):1987-8.
5. Cheraghpour M, Imani H, Omidi S, Alavian SM, Karimi-Shahrbabak E, Hedayati M et al. Hesperidin improves hepatic steatosis, hepatic enzymes, and metabolic and inflammatory parameters in patients with nonalcoholic fatty liver disease: A randomized, placebo-controlled, double-blind clinical trial. *Phytotherapy Research*. 2019; 33(8):2118-25.
6. Huber Y, Galle PR, Schattenberg JM. What is the (right) target for non-alcoholic fatty liver disease (NAFLD)? *Zeitschrift für Gastroenterologie*. 2020;58(1):68-73.
7. Movahhed M, Mosaddegh M, Farsani GM, Abolhasani MH. History of fatty liver in Medieval Iranian Medicine. *Health MED*. 2013;7:786-92.
8. Aghili Khorasani S. Moalejate Aghili. Institute for islamic and complementary medicine, Tehran University of Medical Science. 2008:976-81.
9. Chalasani N, Younossi Z, Lavine JE, Diehl AM, Brunt EM, Cusi K et al. The diagnosis and management of non-alcoholic fatty liver disease: Practice guideline by the American association for the study of liver diseases, American college of gastroenterology, and the american gastroenterological association. *Hepatology*. 2012;55(6):2005-23.
10. Amin G, Khanavi M, Zolfaghari B, Rahimi R, Soltani A, Shams Ardakani M et al. *Avishan Journal of Islamic and Iranian Traditional Medicine*. 2014;4(4):398-403.
11. MH Aghili, Makhzan-al-Advia, Tehran University of Medical Sciences; 2009.

- Available:<http://aqlibrary.org/UserFiles/File/makhzan.pdf> [Persian]
12. Kadan S, Rayan M, Rayan A. Anticancer activity of anise (*Pimpinella anisum* L.) seed extract. The Open Nutraceuticals Journal. 2013;6:1-15.
 13. Al-Howiriny T, Alsheikh A, Alqasoumi S, Al-Yahya M, ElTahir K, Rafatullah S. Gastric antiulcer, antisecretory and cytoprotective properties of celery (*Apium graveolens*) in rats. Pharmaceutical Biology. 2010;48(7):786-93.
 14. Ehsani MJ, Jafari JM, Choopani R, Heydarirad G, Kamalinejad M, Gachk L. Hepatoprotective herbal medicine in Iranian traditional medicine (ITM). Eur J Exp Biol. 2014;4 (3):88-92.
 15. Huang Q, Lu G, Shen HM, Chung MC, Ong CN. Anti-cancer properties of anthraquinones from rhubarb. Medicinal research reviews. 2007;27(5):609-30.

© 2020 Niknafs et al.; This is an Open Access article distributed under the terms of the Creative Commons Attribution License (<http://creativecommons.org/licenses/by/4.0>), which permits unrestricted use, distribution, and reproduction in any medium, provided the original work is properly cited.

Peer-review history:
The peer review history for this paper can be accessed here:
<http://www.sdiarticle4.com/review-history/64237>