



# Case Series on Post Renal Transplant Fungal Infections of the Lung

R. K. Chopra <sup>a++</sup>, Ganesh Pratap <sup>a#</sup>, Rushita D. Nakarani <sup>a†\*</sup>  
and Saumya Gupta <sup>a†</sup>

<sup>a</sup> Department of Pulmonary Medicine, Ruby Hall Clinic, 40, Sasoon Road, Pune, Maharashtra, India.

## Authors' contributions

This work was carried out in collaboration among all authors. All authors read and approved the final manuscript.

## Article Information

DOI: 10.9734/JAMMR/2023/v35i195149

## Open Peer Review History:

This journal follows the Advanced Open Peer Review policy. Identity of the Reviewers, Editor(s) and additional Reviewers, peer review comments, different versions of the manuscript, comments of the editors, etc are available here: <https://www.sdiarticle5.com/review-history/103139>

Case Study

Received: 14/05/2023

Accepted: 16/07/2023

Published: 27/07/2023

## ABSTRACT

Invasive fungal infections are a significant concern for solid organ transplant (SOT) patients, especially those who have undergone small bowel or lung transplants. Renal transplant recipients commonly develop fungal infections like candidiasis, aspergillosis, and cryptococcosis, contributing to post-transplant infections. This case series presents three cases of pulmonary fungal infections after renal transplantation: cryptococcosis, mucormycosis, and invasive pulmonary aspergillosis. The objective is to highlight challenges in diagnosing and managing invasive fungal infections in SOT recipients, emphasizing early diagnosis, timely treatment initiation, and optimized antifungal drug pharmacokinetics for successful outcomes.

**Aims and Objectives:** Include emphasizing the importance of prompt diagnosis and treatment, optimizing antifungal drug pharmacokinetics, and highlighting the need for intensive antifungal therapy in SOT patients with fungal infections.

**Methods:** The cases involve comprehensive clinical information, diagnostic procedures (imaging, endoscopy, biopsies, microscopy, culture, and serologic testing), and treatment approaches.

<sup>++</sup> Senior Consultant; Professor and Head;

<sup>#</sup> Assistant Professor;

<sup>†</sup> Resident;

\*Corresponding author: E-mail: [rushitanakarani@gmail.com](mailto:rushitanakarani@gmail.com);

Antifungal therapy was promptly initiated, even without laboratory confirmation, to ensure timely treatment. Antifungal drug pharmacokinetics were optimized to minimize nephrotoxicity in SOT patients.

**Results:** Case 1 describes a middle-aged obese woman with respiratory symptoms diagnosed with cryptococcosis. Case 2 presents a young male kidney transplant recipient with mucormycosis. Case 3 involves a male patient with cough and hemoptysis diagnosed with invasive pulmonary aspergillosis. All cases received appropriate antifungal therapy, leading to symptom resolution and radiological improvement, although some patients had persistent radiological opacities.

**Discussion:** Diagnosing invasive fungal infections in transplant patients remains challenging, relying on clinical presentation and supportive diagnostic procedures. Management requires a multidisciplinary approach involving antifungal therapy, surgical intervention (if applicable), and control of predisposing factors. Primary treatments included liposomal amphotericin B and voriconazole, considering combination therapy and newer antifungal agents. Early detection and prompt treatment initiation are crucial to reduce mortality rates, especially in disseminated disease.

**Conclusion:** Invasive fungal infections present significant challenges in solid organ transplant recipients. Despite advancements in diagnostics and antifungal therapies, mortality and graft loss rates remain high, particularly in disseminated disease cases. Future research should integrate data from various sources to enhance understanding of fungal pathogenesis, host immune responses, and pharmacological aspects, aiming to develop more effective prevention and treatment strategies for fungal infections in transplant recipients.

**Keywords:** *Post renal transplant; fungal infections; lung; cryptococcosis; mucormycosis; invasive pulmonary aspergillosis; diagnosis; management; antifungal therapy.*

## 1. INTRODUCTION

Invasive fungal infections pose significant challenges for recipients of solid organ transplants (SOT). The epidemiology of fungal infections in transplantation is heavily influenced by host and environmental factors. The highest risk is observed in small bowel (11.6%) and lung (8.6%) transplants, followed by liver (4.7%), heart (4.0%), pancreas (3.4%), and kidney (1.3%) [1]. Several factors affect the risk of developing invasive fungal infections, including the patient's exposure to pathogenic fungi in their environment, colonization by these fungi, the use of antifungal prophylaxis, and the level of immunosuppression. Fungal infections account for approximately 5% of infections in recipients of renal transplants [2-5]. Among these infections, Candidiasis is the most frequent, followed by aspergillosis and cryptococcosis. Invasive aspergillosis is particularly severe and has a poor prognosis, but there is limited research on outcomes [6,7]. Notably, aspergillosis is most commonly seen in lung transplant recipients. The level of immunosuppression varies widely based on the type of transplant received [8-13]. The interplay between host and environmental factors, along with the impact of antifungal prophylaxis strategies, has a more significant influence on the development of specific fungal infections than the time elapsed after transplantation [14,15]. For instance, the median

time to the onset of invasive candidiasis ranges from several weeks to months in lung and liver transplant recipients, but it can exceed two years in kidney recipients [16]. Similarly, the median time to invasive aspergillosis is less than six months in liver transplant recipients, but it occurs much later in kidney, heart, and lung transplant recipients. This delayed onset of invasive aspergillosis in lung transplant recipients is likely due to the widespread use of mould-active prophylaxis in this group [17-19]. Finally, cryptococcosis tends to manifest between 2 and 5 years after transplantation, although it can occur much earlier in cases of donor transmission or significant environmental exposure [16].

Advancements in therapeutic and diagnostic approaches are equipping healthcare providers with unprecedented resources to assess, treat, and prevent invasive fungal infections in solid organ transplant (SOT) recipients [20-26]. Despite these progressions, invasive fungal infections continue to significantly impact the well-being and survival of this patient population. Recent research has yielded new insights into the epidemiology of invasive fungal infections among SOT recipients [1,16,27]. The overall cumulative incidence within the first year after transplantation is approximately 3%, though this varies depending on the specific transplanted organ [1]. However, the risk of infection,

particularly from inhaled fungi, persists for many years following the transplant [28-30]. Present epidemiological trends indicate a shift towards infections occurring later in the post-transplant period. The consequences of fungal infections can be severe, leading to prolonged hospitalizations, damage to the transplanted organ (allograft), and high mortality rates. Data gathered from 15 medical centers involved in a prospective cohort study of invasive fungal infections in SOT recipients indicate that the 12-month mortality rates are approximately 40% for aspergillosis, 34% for candidiasis, and 27% for cryptococcosis [1].

The study conducted on 2020 by Krishan L Gupta, Sahil Bagai, Raja Ramachandran, and Vivek Kumar examined fungal infections in post-renal transplant patients. Amongst 550 renal transplant recipients, the most common invasive fungal infection isolated in their single-center experience was Mucormycosis (26.7%). This was followed by Aspergillosis (23.2%), Pneumocystis jiroveci (21.4%), Cryptococcus (10.7%), Candida (7.1%), Histoplasmosis (5.3%), and Phaeohyphomycosis (3.5%). Additionally, the fungal etiology remained undetermined in (8.9%) of the patients.

Infections caused by geographically restricted endemic fungi are not common, and the main opportunistic fungi responsible for most of these infections include Aspergillus species, Mucorales species, Candida species, mucormycosis, and Cryptococcus neoformans [31-36]. The symptoms of systemic fungal infections are not specific, especially in their early stages. Due to the high rates of mortality and graft loss associated with fungal infections, early diagnosis and treatment are essential, particularly in immunosuppressed patients. Current diagnostic methods for systemic fungal infections encompass imaging procedures, endoscopic techniques, biopsies, microscopic and culture analyses, serologic testing based on antibodies and antigens, and the use of polymerase chain reaction (PCR) to detect fungal DNA in blood or bronchoalveolar lavage fluid. Careful analysis of signs and symptoms is also crucial in the diagnostic process. For patients suspected to have a fungal infection (even before laboratory confirmation), it is vital to promptly initiate antifungal therapy and adjust immunosuppressive regimens as needed [37-42]. Managing fungal infections in post-renal transplant patients presents challenges, and optimizing the pharmacokinetics of antifungal

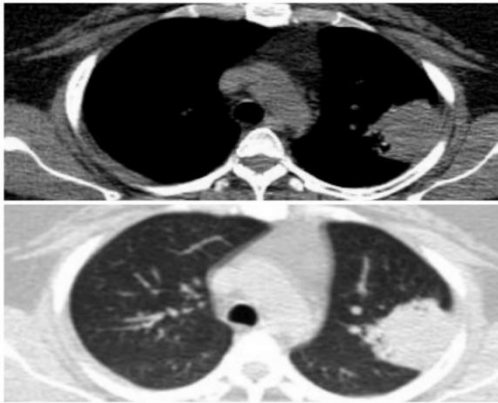
drugs to reduce the risk of kidney damage (nephrotoxicity) is of utmost importance. In this article, we present three cases of post-transplant pulmonary fungal infections.

## 2. CASE PRESENTATION

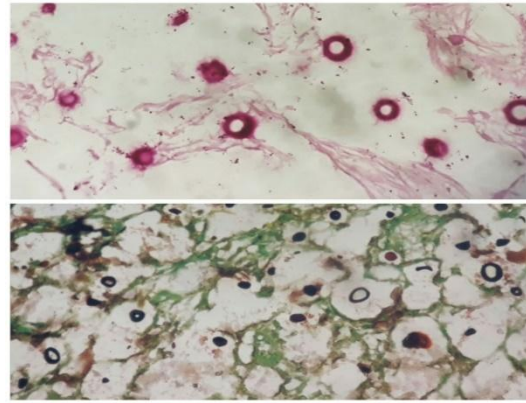
### 2.1 Cryptococcosis

#### 2.1.1 Case 1

A Middle-aged obese lady 6 months post-renal transplant presented to our institute with complaints of dry cough, chest pain and on-off low-grade fever since 1 month. She also had one episode of hemoptysis and complained of reduced appetite. Her general examination was unremarkable. Vitals were also within normal limits. Her respiratory system examination revealed a dull percussion note on the left side with reduced breath sounds in the axillary region. Oxygen saturation was 97% at room air and normal body temperature was recorded. Her routine blood chemistry was within normal limits. She was negative for HIV and any chronic infections. Renal function, liver function, and coagulation studies were within normal limits. She underwent a chest x-ray which showed left upper lobe opacity with blunting of cardio phrenic angle. Her contrast CT scan was also done which showed a peripheral well-defined solid mass lesion in the left upper lobe apical posterior segment with a thin rim of pleural effusion (Fig. 1. a). Pleural fluid was exudative but negative for malignant cells. Her bronchoscopic findings were unremarkable and BAL was negative for any malignant cells and the culture was also sterile. Subsequently, she underwent a CT-guided trans-thoracic biopsy of a solid lesion and the tissue was sent for histopathological examination. Distinctively, it was negative for malignancy but revealed abundant fungal yeast. Gomori's silver Methenamine staining and Mucicarmine staining were carried out which confirmed the presence of cryptococcal infection (Fig. 1. b). She was also found positive for serum cryptococcal antigen. Her blood, urine and CSF culture were negative for cryptococcal. She denied any travel history or any immunosuppressant drug exposure. Her detailed immunological screening was carried out. Her IgG, IgM and IgA levels were within normal limits with normal absolute CD4 counts. She was diagnosed with Cryptococcal pneumonia and treatment was started with Inj. Amphotericin B for 2 weeks followed by oral Fluconazole 400mg BD for 10 weeks. The



**Case 1- Fig. 1. a. A peripheral well-defined solid mass lesion in the left upper lobe apical posterior segment with a thin rim of pleural effusion**



**Case 1- Fig. 1. b. Gomori's silver Methenamine staining and Mucicarmine staining were carried out which confirmed the presence of cryptococcal infection**

patient was followed up after completion of treatment with resolution of symptoms but had persistent radiological opacity.

## 2.2 Mucormycosis

### 2.2.1 Case 2

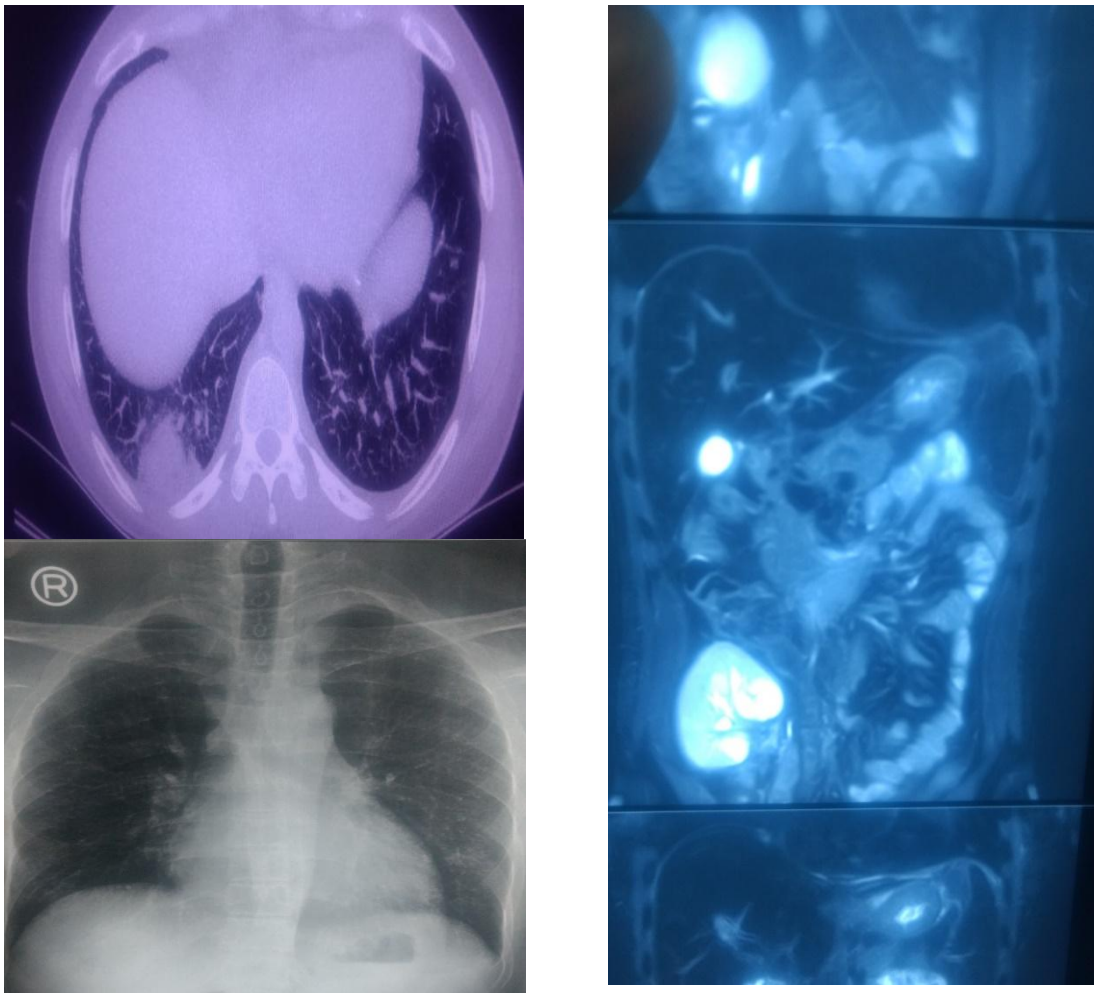
A 24-year-old male presented with progressive generalized weakness and fever for 1 month after receiving a living unrelated kidney transplant for end-stage kidney disease of unclear aetiology. He was maintained on hemodialysis for 5 years prior to the transplant. The patient was on maintenance therapy of immunosuppression consisting of mycophenolate mofetil, tacrolimus, and corticosteroids, in addition to trimethoprim/sulfamethoxazole and valganciclovir for microbial prophylaxis. An evaluation of the transplanted kidney using ct scan of the abdomen was done, which confirmed the mass lesion of 4x5cms as shown in Fig. (2.a) and uppercuts of ct also showed a mass lesion in the right lower lobe basal segments of the lung. A kidney biopsy showed evidence of acute tubular necrosis. CT-guided transthoracic biopsy of the mass lesion was also performed, which revealed mucormycosis. CT of the head showed no involvement of the sino-orbital areas or the brain. The patient was started on liposomal amphotericin B (5 mg/kg daily i.v o.d) with syrup posaconazole per oral 200mg thrice a day for mucormycosis. A cumulative dose of 3 grams of liposomal amphotericin b was administered over 2 weeks. Mycophenolate and tacrolimus were discontinued and the dose of

prednisone was reduced. The patient had an acute increase in levels of serum creatinine levels which was treated with dialysis every third day during treatment with amphotericin b. he became asymptomatic within 3 days of starting the treatment and the lesion showed regression in size repeat ct scan was done after completion of cumulative dose. The patient is on regular follow-up and required dialysis only twice after cumulative dose in 1 month and the patient's serum creatinine level is stable now.

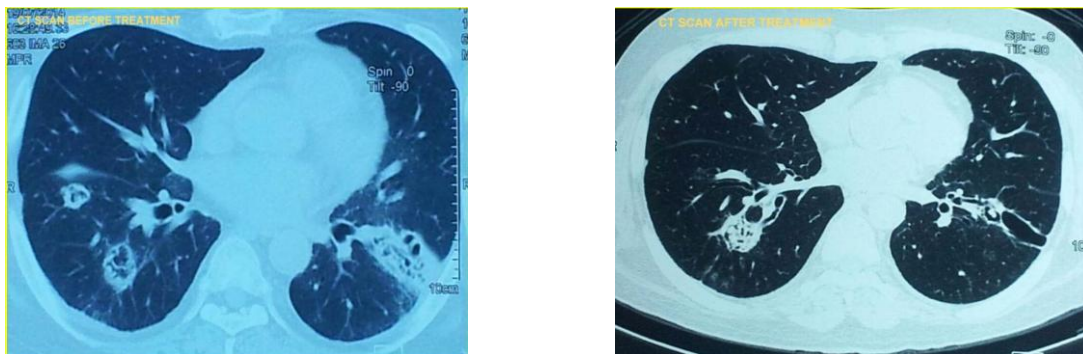
## 2.3 Invasive Pulmonary Aspergillosis

### 2.3.1 Case report 3

Case2-A 43-year-old male presented with cough with expectoration, fever, and haemoptysis for 15 days after 4 years of receiving a cadaver kidney transplant for end-stage kidney disease. The patient was on maintenance therapy of immunosuppression consisting of cyclosporine and corticosteroids. Vital signs in the emergency department were temperature 100.8F, blood pressure 144/66 mm Hg, heart rate 80/min, respiratory rate 30/min, and oxygen saturation 99% on room air. Clinical examination revealed fine crepitations in the bilateral infrascapular area. Laboratory data showed a white cell count of 7000 cells/dl with 82% neutrophils, haemoglobin 10 g/dl, hematocrit 25%, blood urea nitrogen 77 mg/dl, and serum creatinine 3.5 mg/dl. Liver function tests and electrolytes were normal. Electrocardiogram was normal and the chest X-ray showed a b/l cavitory lesion in the lower lobes. The peak expiratory flow rate was 200 L/min. ct scan confirmed the cavitating



**Case 2—Fig. 2. a, 2.b—CT scan of the abdomen confirmed the mass lesion of 4x5cms as shown in Fig. 2. b and uppercuts of CT also showed a mass lesion in the right lower lobe basal segments of the lung in Fig. 2. a**



**Case 3—Fig. 3. A. Cavitating macro nodules with a halo sign in both lower lobes**

macro nodules with a halo sign in both lower lobes. Serum mycoplasma antibody, urine legionella antigen, nasal swab for respiratory syncytial virus and influenza antigen, and rapid streptococcal throat tests were negative.

Bronchoscopy revealed whitish plaques in the lower lobe bronchus. Bal b-galactomannan was highly positive, bronchial washing showed branching hyphae and cultures showed green colour *Aspergillus fumigatus*. Hence the

diagnosis of IPA was confirmed. He was treated with incremental doses of amphotericin b followed by voriconazole 200 for 6 months, follow-up ct scan and clinical improvement were satisfactory.

### 3. DISCUSSION

The presented cases highlight the occurrence of different fungal infections in solid organ transplant recipients, specifically cryptococcosis, mucormycosis, and invasive pulmonary aspergillosis. These cases emphasize the challenges in diagnosing and managing fungal infections in immunocompromised patients.

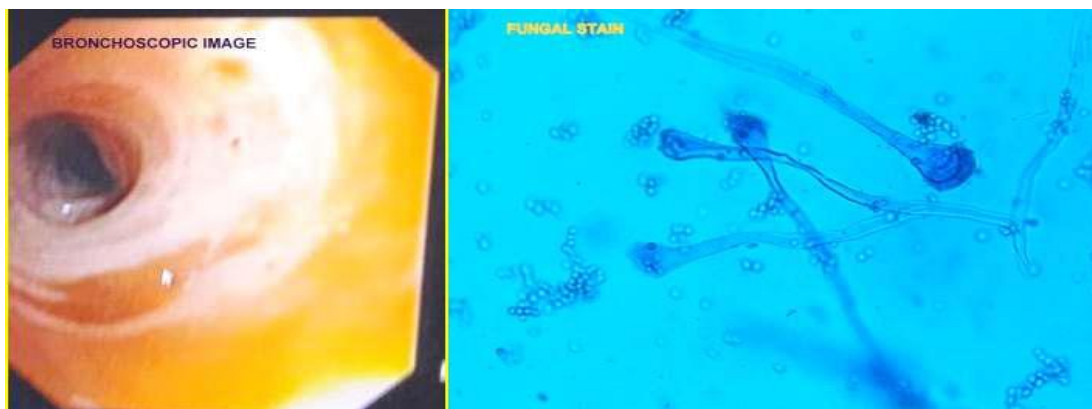
In Case 1, a renal transplant recipient developed cryptococcal pneumonia. The patient presented with respiratory symptoms, and imaging studies revealed a solid mass lesion in the left upper lobe of the lung. Histopathological examination confirmed the presence of cryptococcal infection. The patient received treatment with Amphotericin B followed by Fluconazole, leading to symptom resolution but persistent radiological opacity. This case highlights the importance of considering cryptococcal infection as a potential cause of respiratory symptoms in post-renal transplant patients and the need for prompt diagnosis and appropriate antifungal therapy.

Case 2 involves a renal transplant recipient who developed mucormycosis. The patient presented with generalized weakness and fever. Imaging studies revealed a mass lesion in the transplanted kidney and the lung. Biopsy confirmed the diagnosis of mucormycosis, and

the patient was treated with liposomal Amphotericin B and Posaconazole. The patient showed regression of the lesions and improvement in symptoms. This case underscores the importance of considering mucormycosis as a potential infection in renal transplant recipients, particularly in the presence of immunosuppressive therapy, and highlights the need for prompt diagnosis and aggressive antifungal treatment.

In Case 3, a kidney transplant recipient developed invasive pulmonary aspergillosis (IPA). The patient presented with respiratory symptoms and imaging studies revealed cavitory lesions in the lower lobes of the lungs. Bronchoscopy and microbiological analysis confirmed the diagnosis of IPA. The patient received treatment with Amphotericin B followed by Voriconazole, resulting in clinical improvement. This case emphasizes the challenges in diagnosing IPA in post-kidney transplant patients and highlights the importance of considering this infection in the differential diagnosis of respiratory symptoms.

These cases collectively demonstrate the importance of early recognition and appropriate management of fungal infections in solid organ transplant recipients. Prompt diagnosis, initiation of antifungal therapy, and close monitoring are crucial in improving patient outcomes. Additionally, these cases underscore the need for further research to enhance diagnostic methods, explore novel treatment strategies, and identify preventive measures to reduce the incidence of fungal infections in this vulnerable patient population.



**Case 3-Fig. 3. B. Bronchial washing showed branching hyphae and cultures showed green colour *Aspergillus fumigatus***

### 3.1 IPA

The diagnosis of invasive pulmonary aspergillosis (IPA) presents challenges due to the nonspecific nature of symptoms, often leading to delayed recognition, especially in patients lacking classic risk factors. The 'gold standard' for diagnosis involves tissue biopsy with histopathologic evidence of fungal hyphal invasion [43]. In SOT recipients, IPA can be a devastating complication, resulting in high rates of graft loss and mortality. Data from a prospective cohort study involving 15 medical centers show that the 12-month mortality for SOT recipients with aspergillosis exceeds 50% [1]. *Aspergillus fumigatus* is the most common species causing infection, while *Aspergillus flavus*, *Aspergillus niger*, and *Aspergillus terreus* are less frequently encountered [44,45]. Collecting tissue specimens from critically ill patients, often intubated and hemodynamically unstable, can be challenging. Identification of *Aspergillus* species in sputum may indicate colonization, especially in immunocompetent patients (1, 10). However, in patients with leukemia or those who have undergone SOT, isolation of *Aspergillus* from sputum has a high positive predictive value (80-90%) for the presence of IPA [1,46,47]. Nosocomial transmission leading to colonization and infection has been reported, with aerosolization of spores resulting from wound debridement in a transplant ICU leading to person-to-person transmission. Diagnosing invasive aspergillosis frequently requires histological evidence for infection and culture. Gomori's Methenamine Silver and periodic acid-Schiff staining or fluorescent dyes like Calcofluor white can be used on specimens such as smears and tissue. Immunohistochemistry techniques are promising but not yet widely used. Computed tomographic (CT) scans can be suggestive of IPA in 85% of cases, with pulmonary nodules being the most common abnormality, and the 'halo sign' showing relatively higher specificity and predictive value in neutropenic fever cases after SOT [48]. Laboratory tests detecting *Aspergillus* antigens in serum or bronchoalveolar lavage fluid (BAL) are increasingly helpful for diagnosis. Galactomannan (GM) testing and *Aspergillus* polymerase chain reaction (PCR) in BAL exhibit good sensitivity and specificity for IPA [16,49]. Voriconazole has become the preferred antifungal therapy for IPA after a large clinical trial showed higher response rates and survival compared to amphotericin (71% vs. 58%) at 12 weeks of treatment, along with a better side

effect profile and tolerability. Echinocandins like caspofungin are used as salvage therapy for patients unresponsive or intolerant to first-line therapy [1]. Combination therapy with azoles, trienes, and echinocandins could be considered in certain cases [1]. Prolonged and high-dose corticosteroid therapy is a known risk factor for IPA development, likely due to inhibiting macrophage killing of *Aspergillus* and promoting its growth p [1,16,50,51]. Although IPA can be seen in patients with chronic lung diseases on long-term steroids, it is rarely observed with short-term corticosteroid use [1,16,52].

### 3.2 Mucormycosis

The most common form of mucormycosis is rhino-cerebral, followed by pulmonary infection. The overall mortality rate for mucormycosis is 52%, with a higher mortality rate observed in recipients with pulmonary infection (100%), while the rhino-cerebral form has a lower mortality rate (30.8%). There were no statistically significant differences in mortality rates between males and females, age groups, or time of diagnosis since transplantation. Pulmonary infection was more frequently observed in recipients receiving azathioprine compared to those on mycophenolate mofetil. Mucorales are generally harmless in immunocompetent individuals, except in cases of uncontrolled diabetes mellitus, heavy exposure in natural disasters, or rarely without apparent predisposing factors. However, recipients of solid organ transplants (SOT) are at higher risk due to their immunosuppressed state. Diabetes mellitus remains a leading risk factor, and immunosuppression, especially through T cell depleting agents, also increases the risk of mucormycosis. The most common species causing mucormycosis varies regionally, with *Rhizopus* species being the most common. The infection is acquired through inhalation of spores or direct contact with the skin, leading to angioinvasive hyphae causing hemorrhagic necrosis, vascular thrombosis, and tissue infarction.

Among SOT recipients, pulmonary infection is the predominant site affected by mucormycosis, accounting for 39% of cases, with involvement of other organ sites in 48%. Disseminated disease occurs in 9–26% of cases in the SOT population, with liver transplant recipients having the highest incidence. Timely diagnosis of mucormycosis is challenging due to the non-specific clinical presentation, and early initiation of treatment is crucial for better survival. Diagnostic confirmation

involves a combination of radiological, histological, and microbiological studies, with PCR being used for early detection and identification of the fungus. Amphotericin B (AmB) and posaconazole are the antifungal agents active against Mucorales. AmB is considered the drug of choice, with liposomal AmB having better safety and activity profile compared to conventional AmB. Surgery is an essential part of management for localized disease, while combination therapies have been attempted, showing promising results. Isavuconazole is a new antifungal agent with good in vitro activity against Mucorales, currently being evaluated in clinical trials.

The overall mortality rate of mucormycosis ranges from 38% to 56.5%, with dissemination leading to a marked increase in mortality, up to 100%. Mortality rates vary depending on the site of infection, being higher in disseminated cases and isolated pulmonary infections. Routine prophylaxis against fungal infections in kidney transplant recipients is not currently recommended.

#### **4. CONCLUSION & FUTURE PERSPECTIVE**

Invasive fungal infections are a significant problem for people who have received solid organ transplants. These infections can cause severe illness and even death. This study provides important information about how these infections occur, how they are diagnosed, and how they are treated. It emphasizes the need to consider factors related to the person receiving the transplant and the environment in which they live when thinking about fungal infections. The study shows that certain types of transplants, such as small bowel and lung transplants, carry a higher risk of fungal infections compared to other types of organ transplants. This information is crucial for doctors to assess the risk for each patient and develop strategies to prevent infections.

The study also reveals that the way fungal infections present and develop can vary depending on the type of transplant. Understanding these differences can help doctors develop targeted ways to monitor and prevent infections. The study includes examples of patients who developed fungal infections after their transplants, providing important insights into how these infections are diagnosed and managed. The study highlights the importance of

starting antifungal treatment early in suspected cases, even before laboratory tests confirm the infection. Early treatment is essential for better outcomes and to prevent complications. The study also emphasizes the need to adjust the doses of antifungal drugs in patients who have received kidney transplants to reduce the risk of kidney damage.

In conclusion, this study emphasizes the significant impact of invasive fungal infections on people who have received solid organ transplants. It highlights the need for better ways to diagnose and treat these infections. The study suggests that future research should focus on developing new diagnostic tools, evaluating combinations of different drugs for treatment, and understanding how the risk of these infections may change over time. Improving our understanding and treatment of fungal infections will help improve outcomes and reduce the harm caused by these infections in transplant recipients.

#### **CONSENT**

As per international standard or university standard, patient(s) written consent has been collected and preserved by the author(s).

#### **ETHICAL APPROVAL**

As per international standard or university standard written ethical approval has been collected and preserved by the author(s).

#### **COMPETING INTERESTS**

Authors have declared that they have no known competing financial interests OR non-financial interests OR personal relationships that could have appeared to influence the work reported in this paper.

#### **REFERENCES**

1. Capoor M, Nair D, Deb M, Gupta B, Aggarwal P. Clinical and mycological profile of cryptococcosis in a tertiary care hospital. *Indian Journal of Medical Microbiology*. 2007;25(4):401–404.
2. Chandrasekar P. Invasive mold infections: Recent advances in management approaches. *Leuk Lymphoma*. 2009; 50(5):703-15.
3. Pini G, Faggi E, Donato R, Sacco C, Fanci R. Invasive pulmonary aspergillosis in



- neutropenic patients and the influence of hospital renovation. *Mycoses*. 2008; 51(2):117-22.
4. Lambourne J, Agranoff D, Herbrecht R, Troke PF, Buchbinder A, Willis F, et al. Association of mannose-binding lectin deficiency with acute invasive aspergillosis in immunocompromised patients. *Clin Infect Dis*. 2009;49(10):1486-91.
  5. Shelhamer JH, Gill VJ, Quinn TC, Crawford SW, Kovacs JA, Masur H, et al. The laboratory evaluation of opportunistic pulmonary infections. *Ann Intern Med*. 1996;124(6):585-99.
  6. Nunez M, Peacock JE, Chin R. Pulmonary cryptococcosis in the immunocompetent host: Therapy with oral fluconazole—A report of four cases and a review of the literature. *Chest*. 2000;118(2):527–534.
  7. Nadrous H, Antonios V, Terrell C, Ryu J. Pulmonary cryptococcosis in non-immunocompromised patients. *Chest*. 2003;124:2143–7.
  8. Singh N, Gayowski T, Singh J, Yu VL. Invasive gastrointestinal zygomycosis in a liver transplant recipient: case report and review of zygomycosis in solid-organ transplant recipients. *Clin Infect Dis*. 1995;20(3):617–20.
  9. Marr KA, Carter RA, Crippa F, et al. Epidemiology and outcome of mould infections in hematopoietic stem cell transplant recipients. *Clin Infect Dis*. 2002;34(7):909–17.
  10. Stelzmueller I, Lass-Floerl C, Geltner C, et al. Zygomycosis and other rare filamentous fungal infections in solid organ transplant recipients. *Transpl Int*. 2008; 21(6):534–46.
  11. Nouri-Majalan N, Moghimi M. Skin mucormycosis presenting as an erythema-nodosum-like rash in a renal transplant recipient: A case report. *J Med Case Reports*. 2008;2:112.
  12. Page AV, Evans AJ, Snell L, Liles WC: Primary cutaneous mucormycosis in a lung transplant recipient: Case report and concise review of the literature. *Transpl Infect Dis*. 2008;10(6):419–25.
  13. Original Paper *Ann Transplant*. 2011; 16(3):44-48.
  14. Fisher JF, Valencia-Rey PA, Davis WB. Pulmonary Cryptococcosis in the Immunocompetent Patient—Many Questions, Some Answers. In *Open forum infectious diseases*. 2016;3(3): p. ofw167). Oxford University Press.
  15. Lake KB, Browne PM, Van Dyke JJ, Ayers L. Fatal disseminated aspergillosis in an asthmatic patient treated with corticosteroids. *Chest*. 1983;83(1):138-9.
  16. Banerjee U, Datta K, Casadevall A. Serotype distribution of *Cryptococcus neoformans* in patients in a tertiary care center in India. *Medical Mycology*. 2004; 42(2):181-6.
  17. Hammerman KJ, Powell KE, Christianson CS, et al. Pulmonary cryptococcosis: Clinical forms and treatment. *Am Rev Respir Dis*. 1973;108:1116–1123.
  18. Robinson GR II. Severe cryptococcal pneumonia. *N Engl J Med*. 1995;332:1752.
  19. Fox DL, Müller NL. Pulmonary cryptococcosis in immunocompetent patients: CT findings in 12 patients. *AJR*. 2005;185:622–626
  20. Patterson TF, Kirkpatrick WR, White M, Hiemenz JW, Wingard JR, Dupont B, et al. Invasive aspergillosis. Disease spectrum, treatment practices, and outcomes. I3 *Aspergillus Study Group*. *Medicine (Baltimore)*. 2000;79(4):250-60.
  21. Yeghen T, Kibbler CC, Prentice HG, Berger LA, Wallesby RK, McWhinney PH, et al. Management of invasive pulmonary aspergillosis in hematology patients: A review of 87 consecutive cases at a single institution. *Clin Infect Dis*. 2000;31(4):859-68.
  22. Hoenigl M, Prattes J, Spiess B, Wagner J, Pruellner F, Raggam RB, et al. Performance of galactomannan, beta-d-glucan, *Aspergillus* lateral-flow device, conventional culture, and PCR tests with bronchoalveolar lavage fluid for diagnosis of invasive pulmonary aspergillosis. *J Clin Microbiol*. 2014;52(6):2039\_45.
  23. De Pauw B, Walsh TJ, Donnelly JP, Stevens DA, Edwards JE, Calandra T, et al. Revised definitions of invasive fungal disease from the European organization for research and treatment of cancer/invasive fungal infections cooperative group and the national institute of allergy and infectious diseases mycoses study group (EORTC/MSG) Consensus Group. *Clin Infect Dis*. 2008;46(12):1813-21. DOI: 10.1086/588660.
  24. Bulpa P, Dive A, Sibille Y. Invasive pulmonary aspergillosis in patients with chronic obstructive pulmonary disease. *Eur Respir J*. 2007;30(4):782-800.

25. Fukuda T, Boeckh M, Carter RA, Sandmaier BM, Maris MB, Maloney DG, et al. Risks and outcomes of invasive fungal infections in recipients of allogeneic hematopoietic stem cell transplants after nonmyeloablative conditioning. *Blood*. 2003;102(3):827-33.
26. Herbrecht R, Denning DW, Patterson TF, Bennett JE, Greene RE, Oestmann JW, et al. Invasive fungal infections group of the European Organisation for Research and Treatment of Cancer and the Global Aspergillus Study Group. Voriconazole versus amphotericin B for primary therapy of invasive aspergillosis. *N Engl J Med*. 2002;347(6):408-15.
27. Matsushita T, Suzuki K. Spastic paraparesis due to cryptococcal osteomyelitis: A case report. *Clinical Orthopaedics and Related Research*. 1985;196:279-284.
28. Schaffner A, Schaffner T. Glucocorticoid-induced impairment of macrophage antimicrobial activity: Mechanisms and dependence on the state of activation. *Rev Infect Dis*. 1987;9(Suppl 5):S620-9.
29. Ng TT, Robson GD, Denning DW. Hydrocortisone-enhanced growth of aspergillus spp.: Implications for pathogenesis. *Microbiology*. 1994;140(Pt 9):2475-9.
30. Cornet M, Mallat H, Somme D, Gue'rot E, Kac G, Mainardi JL, et al. Fulminant invasive pulmonary aspergillosis in immunocompetent patients \_ A two-case report. *Clin Microbiol Infect*. 2003;9(12):1224-7.
31. Lopes Bezerra LM, Filler SG. Interactions of *Aspergillus fumigatus* with endothelial cells: Internalization, injury, and stimulation of tissue factor activity. *Blood*. 2004;103(6):2143-9.
32. Einollahi B, Lessan-Pezeshki M, Pourfarziani V, et al. Invasive fungal infections following renal transplantation: A review of 2410 recipients. *Ann Transpl*. 2008;13(4):55-58.
33. Chkhotua A, Yussim A, Tovar A, et al. Mucormycosis of the renal allograft: Case report and review of the literature. *Transpl Int*. 2001;14(6):438-41.
34. Nampoory MR, Khan ZU, Johny KV, et al. Invasive fungal infections in renal transplant recipients. *J Infect*. 1996;33(2):95-101.
35. Grossi PA: Clinical aspects of invasive candidiasis in solid organ transplant recipients. *Drugs*. 2009;69(Suppl.1):15-20.
36. Almyroudis NG, Sutton DA, Linden P et al: Zygomycosis in solid organ transplant recipients in a tertiary transplant center and review of the literature. *Am J Transplant*. 2006;6(10):2365-74.
37. Aslani J, Eizadi M, Kardavani B, et al. Mucormycosis after kidney transplantations: Report of seven cases. *Scand J Infect Dis*. 2007;39(8):703-6.
38. Roden MM, Zaoutis TE, Buchanan WL, et al. Epidemiology and outcome of zygomycosis: A review of 929 reported cases. *Clinical Infectious Diseases*. 2005;41(5):634-53.
39. Einollahi B, et al. Two decades of experience in Mucormycosis after... 47. *Ann Transplant*. 2011;16(3):44-48.
40. Kubak BM, Huprikar SS: Emerging & rare fungal infections in solid organ transplant recipients. *Am J Transplant*. 2009;9(Suppl.4):S208-26
41. Ghadiani MH, Ahmadpour P, Lessan-Pezeshki M et al: Mucormycosis after Living Donor Kidney Transplantation: A Multicenter Retrospective Study. *Int J Nephrol Urol*. 2009;1(1):39-44.
42. Kontoyiannis DP, Wessel VC, Bodey GP, Rolston KV: Zygomycosis in the 1990s in a tertiary-care cancer center. *Clin Infect Dis*. 2000;30(6):851-56.
43. McAdams HP, Rosado-de-Christenson ML, Templeton PA, Lesar M, Moran CA. Thoracic mycosis from opportunistic fungi: Radiologic-pathologic correlation. *RadioGraphics*. 1995;15:271-286.
44. Slesiona S, Gressler M, Mihlan M, Zaehle C, Schaller M, Barz D, Hube B, Jacobsen ID, Brock M. Persistence versus escape: *Aspergillus terreus* and *Aspergillus fumigatus* employ different strategies during interactions with macrophages. *PloS one*. 2012 Feb 3;7(2):e31223.
45. Krishnan S, Manavathu EK, Chandrasekar PH. *Aspergillus flavus*: an emerging non-fumigatus *Aspergillus* species of significance. *Mycoses*. 2009 May;52(3):206-22.
46. Perfect J, Dismukes W, Dromer F, et al. Clinical practice guidelines for the management of cryptococcal disease: Update by the Infectious Diseases Society of America. *Clin Infect Dis*. 2010;50:291-322.

47. Kosmidis C, Denning DW. The clinical spectrum of pulmonary aspergillosis. *Thorax*. 2014;pii: thoraxjnl-2014-206291. DOI: 10.1136/thoraxjnl-2014-206291.
48. Choi YR, Kim JT, Kim JE, Jung HW, Choe KH, Lee KM, et al. Invasive aspergillosis involving the lungs and brain after short period of steroid injection: A case report. *Tuberc Respir Dis(Seoul)*. 2012;72(5): 448-51.
49. Steinbach WJ, Marr KA, Anaissie EJ, Azie N, Quan SP, Meier-Kriesche HU, et al. Clinical epidemiology of 960 patients with invasive aspergillosis from the PATH Alliance registry. *J Infect*. 2012;65(5): 453-64.
50. Soubani AO, Khanchandani G, Ahmed HP. Clinical significance of lower respiratory tract *Aspergillus* culture in elderly hospitalized patients. *Eur J Clin Microbiol Infect Dis*. 2004;23(6): 491-4.
51. Horvath JA, Dummer S. The use of respiratory-tract cultures in the diagnosis of invasive pulmonary aspergillosis. *Am J Med*. 1996;100(2):171\_8.
52. Yu VL, Muder RR, Poorsattar A. Significance of isolation of aspergillus from the respiratory tract in diagnosis of invasive pulmonary aspergillosis. Results from a three-year prospective study. *Am J Med*. 1986;81:249-54.

© 2023 Chopra et al.; This is an Open Access article distributed under the terms of the Creative Commons Attribution License (<http://creativecommons.org/licenses/by/4.0>), which permits unrestricted use, distribution, and reproduction in any medium, provided the original work is properly cited.

*Peer-review history:*  
The peer review history for this paper can be accessed here:  
<https://www.sdiarticle5.com/review-history/103139>