

Giant Retina Tear in an African Population: Presentation and Fellow Eyes

Ogugua N. Okonkwo^{1*}, Adekunle O. Hassan¹, Gyasi E. Michael², Banji Oluyadi³, Adunola Ogunro³, Olufemi Oderinlo¹, Mildred Ulaikere³, Ayodele Harriman³

¹Eye Foundation Retina Institute, Lagos, Nigeria

²St. Thomas Eye Hospital, Accra, Ghana

³Eye Foundation Hospital, Lagos, Nigeria

Email: *o_okonkwo@yahoo.com

How to cite this paper: Okonkwo, O.N., Hassan, A.O., Michael, G.E., Oluyadi, B., Ogunro, A., Oderinlo, O., Ulaikere, M. and Harriman, A. (2017) Giant Retina Tear in an African Population: Presentation and Fellow Eyes. *Open Journal of Ophthalmology*, 7, 129-137.
<https://doi.org/10.4236/ojoph.2017.72018>

Received: March 7, 2017

Accepted: May 28, 2017

Published: May 31, 2017

Copyright © 2017 by authors and Scientific Research Publishing Inc. This work is licensed under the Creative Commons Attribution International License (CC BY 4.0).

<http://creativecommons.org/licenses/by/4.0/>



Open Access

Abstract

Aim: To examine the profile and presentation of a consecutive series of giant retinal tears (GRTs) in an African population. Also to review the clinical state of the patient's fellow eyes. **Method:** A retrospective observational case series of thirty-six consecutive eyes of 36 patients with a GRT retina detachment that had vitreoretina surgery done between April 2006 and June 2013. All information was extracted from the patient's case records. **Result:** Thirty-nine case records had surgery consecutively within the study period. Three case records had incomplete data and were excluded from the analysis. Thirty-six eyes were analyzed. There were mostly males (80.6%), age range 21 - 65 yrs (mean age 47 yrs). The commonest etiology was idiopathic (21 eyes). Presenting visual acuity was mostly in the counting finger and hand motion range (83%), and the mean presenting intraocular pressure was 6.8 mmHg. Most of the eyes presented with a total retina detachment (4 quadrant involvement; 56%), macular involvement (96%), commonest size of the retina tear being between 90 to 180 degrees in 20 eyes; rolled over retina flap (61%) and advanced grades of PVR being very common (83%). The commonest fellow eye event noted was blindness in 16 fellow eyes; while 12 eyes had prophylactic retina laser photocoagulation to peripheral predisposing retina lesions. **Conclusion:** The presentation of GRT in a low resource country is often as a complex retina detachment situation, which may arise from frequent delays to assess care and other socioeconomic issues. This carries significant implications on prognosis following surgical intervention. Also this study raises the awareness that fellow eyes of GRT in Africa are at increased risk of blindness and require more careful attention.

Keywords

Giant Retina Tear, Retina Detachment, Proliferative Vitreoretinopathy, Fellow Eyes

1. Introduction

Giant retina tear represents one of the more complex forms of retina tears and detachment. It is defined as a tear involving three or more clock hours or greater than 90 degrees in the presence of a posterior vitreous detachment (PVD). Though cases of giant retina tear and detachment have been reported in several publications from western, wealthier nations, not much is known about the presentation of giant retina tear and detachment cases, the fellow eye and the surgical repair in an African context [1] [2] [3] [4]. The delay in presentation by the patients and scarce resources could prove to be a challenge in giant retina tear cases which are known to have a higher incidence of proliferative vitreoretinopathy (PVR) and are prone to recurrent retina detachment.

This report is presented in 2 parts. The first part examines the presentation of giant retina tear detachment eyes and reviews their fellow eyes. The second part will examine the outcome of surgical repair of these cases. A review of the presentation of these eyes and the fellow eye in an African population will provide a better understanding of the presentation of this condition in the region and help contrast the situation from that in other regions.

2. Study Aim

The aim of this study is to report the presentation of giant retina tear detachment in a low resource setting as well as to report the events in the fellow eye over the study period.

3. Method

A retrospective observational case series was performed using consecutive eyes that presented with giant retina tear detachment and that had undergone a vitrectomy for repair of the detached retina from April 2006 to June 2013. These cases were identified from the surgical log of the Eye Foundation Retina Institute in Lagos, Nigeria and the case records were then retrieved. The study was approved by the institutional review board (IRB) of the Eye Foundation Retina Institute. The information extracted from the case records include; age, sex, laterality, preoperative visual acuity, predominant quadrant involvement of the retina detachment, intraocular pressure at presentation, size of the giant retina tear, presence of rolled over edge of the detached retina, presence and grade of proliferative vitreoretinopathy (PVR) and macular involvement. The state of the fellow eye as at the time of data collection was specifically researched and information from the case notes was categorized into 3 as {a} being normal (if there was no indication of any ocular pathology), {b} having undergone prophylactic retina laser or any other retina intervention or {c} being blind or visually impaired. Other information sought includes etiology of giant tear and lens status.

Surgical information of relevance extracted included encirclement buckle use, relaxing retinectomy, prior vitrectomy and surgical outcome. Data was analyzed using the *epi info* version 7.2 statistical package.

For the purpose of this study, only information regarding clinical presentation of the giant retina tear detachment and fellow eye is reported. Information regarding surgery and outcome is intentionally omitted as it is beyond the scope of this paper.

4. Results

Thirty-nine eyes of 39 patients were identified from the operating room log as having had vitrectomy for giant retina tear within the study period. Of this number, three eyes had incomplete data and so were excluded from the study. There were therefore thirty-six eyes of 36 patients used for the study analysis. **Table 1** gives a summary of all the parameters assessed for the patients and eyes.

Age range of study participants was within 21 to 65 years. The mean age was 47 years.

There were 29 males (80.6%), with a male to female ratio of 4:1. The number of right eyes was 13, and left eyes were 23 eyes. Majority of the eyes had poor vision at presentation; with 30 eyes (83%) presenting with HM or CF vision. One eye each had a visual acuity of 6/6, 6/18, 6/24 and 6/60.

The mean intraocular pressure at presentation was 6.8 mmHg.

Twenty eyes had a significant cataract while twelve eyes were phakic but without a cataract. One eye was aphakic and 3 eyes were pseudophakic.

A majority of the eyes, 22 of 36 (61%) had a rolled over retina flap at presentation.

The primary quadratic involvement of the retina detachment was inferior in 3 eyes, superior in 3 eyes, supero-temporal in 2 eyes, supero-nasal in 1 eye, temporal in 7 eyes, and a total retinal detachment (with involvement of all 4 quadrants) seen in 20 eyes (56%).

The etiology of the giant retina tear was idiopathic 21 eyes, trauma 8 eyes and myopia 7 eyes.

There was a high rate of advanced proliferative vitreoretinopathy (PVR). Seven eyes had grade B PVR. Advanced stage of PVR grades C and D was seen in twenty-six and three eyes respectively. In all, 29 (83%) of 36 eyes had advanced PVR.

The size of the giant tear was categorized into three which are 90 degrees in 4 eyes; 90 to 180 degrees seen in 20 eyes and greater than 180 degrees in 12 eyes. There was macular involvement in 35 eyes (97%).

As regards the fellow eyes, close to a half of the fellow eyes 16 eyes (44%) were blind with vision of hand motion or worse; while 12 fellow eyes had undergone prophylactic retinal laser photocoagulation to a predisposing peripheral retina degeneration or retina tear. Two eyes had been diagnosed to have a retina detachment (of which one had a giant retina tear detachment). The fellow eyes were judged to be normal in only 5 eyes (14%).

5. Discussion

The incidence of GRTs in large population-based studies has been estimated as 1.5% of rhegmatogenous retinal detachments, with a significant male prepon-

Table 1. Summarizing the findings at presentation of the 36 giant retina detachment eyes.

ID	AGE (Yrs.)	SEX	EYE	PREOP VA	RD QUAD.	ROLLED RETINA FLAP	AETIOLOGY	LENS STATUS	PRE OP IOP (mmHg)	PVR GRADE	SIZE OF TEAR	MACULAR OFF	FELLOW EYE
1	60	MALE	RIGHT	HM	SUPERIO-TEMPORAL	YES	IDIOPATHIC	PHAKIC CATARACT	4	C	90 - 180	YES	LASER
2	21	MALE	LEFT	HM	TOTAL	NO	TRAUMA	PHAKIC CATARACT	4	B	90	YES	BLIND
3	48	MALE	LEFT	HM	TOTAL	NO	IDIOPATHIC	PHAKIC CATARACT	10	C	90 - 180	YES	LASER
4	46	MALE	RIGHT	6/6	SUPERIO-NASAL	NO	IDIOPATHIC	PHAKIC NO CATARACT	6	B	90 - 180	NO	GIANT TEAR, RETINAL DETACHMENT
5	60	MALE	LEFT	CF	TEMPORAL	YES	IDIOPATHIC	PHAKIC NO CATARACT	12	C	>180	YES	BLIND
6	17	FEMALE	RIGHT	HM	TOTAL	YES	TRAUMA	APHAKIC	4	C	>180	YES	BLIND
7	12	FEMALE	LEFT	6/24	TOTAL	YES	MYOPIA	PHAKIC NO CATARACT	8	C	90 - 180	YES	BLIND
8	60	MALE	LEFT	CF	TOTAL	YES	IDIOPATHIC	PHAKIC CATARACT	6	C	>180	YES	RETINAL DETACHMENT VITRECTOMY SURGERY
9	40	MALE	RIGHT	6/18	SUPERIO-TEMPORAL	YES	MYOPIA	PHAKIC NO CATARACT	10	C	>180	YES	LASER
10	45	FEMALE	LEFT	CF	INFERIOR	NO	MYOPIA	PHAKIC CATARACT	0	C	90 - 180	YES	BLIND
11	38	MALE	LEFT	CF	TEMPORAL	NO	MYOPIA	PHAKIC CATARACT	6	C	90 - 180	YES	BLIND
12	46	MALE	LEFT	CF	TEMPORAL	NO	IDIOPATHIC	PHAKIC CATARACT		B	90	YES	LASER
13	58	MALE	RIGHT	HM	TOTAL	NO	IDIOPATHIC	PHAKIC CATARACT	8	C	90 - 180	YES	NORMAL
14	51	MALE	LEFT	CF	TOTAL	YES	TRAUMA	PHAKIC CATARACT	7	C	90 - 180	YES	NORMAL
15	52	MALE	RIGHT	CF	SUPERIOR	NO	IDIOPATHIC	PHAKIC NO CATARACT	10	C	90 - 180	YES	LASER
16	53	FEMALE	LEFT	6/60	SUPERIOR	YES	TRAUMA	PHAKIC CATARACT	11	B	90 - 180	YES	LASER
17	44	MALE	LEFT	CF	INFERIOR	NO	MYOPIA	PHAKIC NO CATARACT	10	B	90	YES	LASER
18	65	FEMALE	RIGHT	PL	TOTAL	NO	IDIOPATHIC	PHAKIC CATARACT	12	C	90 - 180	YES	BLIND
19	52	MALE	RIGHT	CF	TEMPORAL	YES	IDIOPATHIC	PSEUDOPHAKIC	15	C	90 - 180	YES	BLIND
20	64	FEMALE	LEFT	CF	TOTAL	YES	IDIOPATHIC	PHAKIC NO CATARACT	7	C	90 - 180	YES	NORMAL
21	54	MALE	RIGHT	HM	TEMPORAL	YES	IDIOPATHIC	PHAKIC CATARACT	8	C	90 - 180	YES	BLIND

Continued

22	54	MALE	LEFT	HM	TOTAL	YES	IDIOPATHIC	PHAKIC NO CATARACT	3	C	90 - 180	YES	LASER	
23	42	MALE	LEFT	CF	TEMPORAL	YES	IDIOPATHIC	PHAKIC NO CATARACT	1	C	>180	YES	LASER	
24	51	MALE	RIGHT	HM	TOTAL	YES	IDIOPATHIC	PHAKIC CATARACT	10	B	>180	YES	LASER	
25	24	MALE	LEFT	PL	TOTAL, + VITREOUS HAEMORRHAGE	YES	TRAUMA	PHAKIC CATARACT	7	D	>180	YES	NORMAL	
26	47	MALE	RIGHT	HM	TOTAL	NO	MYOPIA	PHAKIC CATARACT	2	C	>180	YES	LASER	
27	61	MALE	LEFT	HM	TOTAL	YES	IDIOPATHIC	PHAKIC CATARACT	8	D	>180	YES	BLIND	
28	39	MALE	RIGHT	HM	TOTAL	YES	TRAUMA	PHAKIC NO CATARACT	8	C	90 - 180	YES	BLIND	
29	45	FEMALE	LEFT	CF	TOTAL	NO	MYOPIA	PHAKIC CATARACT	0	C	90 - 180	YES	BLIND	
30	39	MALE	LEFT	PL	TOTAL	YES	TRAUMA	PHAKIC NO CATARACT	7	C	>180	YES	NORMAL	
31	34	MALE	RIGHT	CF	TOTAL	YES	IDIOPATHIC	PSEUDOPHAKIC	12	B	>180	YES	BLIND	
32	41	MALE	LEFT	HM	TEMPORAL	YES	IDIOPATHIC	PHAKIC CATARACT	6	C	90 - 180	YES	BLIND	
33	57	MALE	LEFT	HM	INFERIOR	NO	IDIOPATHIC	PSEUDOPHAKIC	6	C	90 - 180	YES	RETINAL DETACHMENT	
34	53	MALE	LEFT	HM	TOTAL	YES	IDIOPATHIC	PHAKIC CATARACT	8	C	>180	YES	BLIND	
35	42	MALE	LEFT	HM	SUPERIOR	NO	IDIOPATHIC	PHAKIC NO CATARACT	6	C	90	YES	LASER	
36	24	MALE	LEFT	CF	TOTAL	YES	TRAUMA	PHAKIC CATARACT	6	D	90 - 180	YES	BLIND	
TOTAL									1691					248
AVERAGE/MEAN									46.97 = 47					6.88

derance, and bilaterality in 12.8% [5]. Most GRTs are idiopathic, with trauma, hereditary vitreoretinopathies and high myopia each being causative in decreasing frequency [5].

The annual incidence of giant retina tears (GRT) in the United Kingdom is 0.094 cases or 0.091 patients per 100,000 [6]. In another report from Scotland, GRT accounted for 1.3% of the total rhegmatogenous retinal detachments seen within a 2 year period [7]. The incidence of GRT with or without a retina detachment in an African population is not known. However in this series, 39 eyes had undergone vitreoretina surgery within the study period (complete records for three eyes could not be obtained and were excluded from the analysis).

A study from East Africa reported the presence of giant retina tears in 8.3% of the 361 retina detachment eyes recruited for the study [8]. Our study represents the first attempt at examining the profile of patients and presentation of an exclusive group of giant retina tear detached eyes and the fellow eyes in a black African population.

Giant retinal tear associated with retina detachment presented in this study mostly as a complex form of retina detachment situation. This can be inferred by the predominant severely reduced preoperative visual acuity (83%), high rate of total retina detachment (56%), macular involvement (97%) and a high rate of advanced PVR (83% of eyes at presentation already had advanced stages of PVR C or D).

As in other studies, the male preponderance of GRT is also evident in this study [5].

Idiopathic GRT, which has been noted as the commonest etiology by other studies, also occurred in the majority of eyes in this study [4] [5].

A giant retina tear is a visually debilitating disease and apt to cause blindness in an African situation as is seen by the high number of patients with counting fingers and hand motion vision, 30 out of 36 in this series. These patients are legally blind in this eye. As has been reported previously, retina detachment cases in Africa often present with vision being affected, and can be quite poor in this category of patients, and our series confirms this [9].

Similarly the extreme poor preoperative visual acuity noted in this group is similar to that documented in another study from Egypt [4]. In this study on GRT reported by Sheriff; of the 24 participating eyes, only 3 eyes with attached macula had a readable visual acuity. Preoperative best-corrected visual acuity (BCVA) ranged from hand motion (HM) to counting fingers (CF) in 21 macula-off eyes, while decimal BCVA in eyes with attached macula was 0.15 in two eyes and 0.05 in one eye [4].

This poor preoperative vision may be as a result of delay in presentation as has been noted previously [8] [9]. Also, the fact that all the eyes but one in our series had macular involvement at presentation explains the poor vision. This poor visual acuity non-the less will have a direct effect on the final postoperative visual prognosis [8].

A majority of the eyes had a rolled over retina at presentation. This suggests that intraoperative techniques to unroll the retina will be required. Perfluorocarbon liquids (PFCL) as popularized by Stanley Chang have found important use in unrolling the rolled over retina in GRT cases [10] [11]. It is worthy of note that the 4 eyes with a GRT of 90 degrees, did not have a rolled over retina. This suggests that the retina may not roll over in smaller size GRT as compared to larger GRTs. There were more eyes having a GRT size within 90 - 180 degrees than the other 2 size categorizations (*i.e.* 90 degrees and >180 degrees). The reason for this is unclear.

Nearly all the patients (94%) had a macular involving retina detachment at presentation limiting the expected visual recovery following eventual surgical

intervention. This again demonstrates another difficulty observed with presentation of these cases in a low resource setting. This situation may be as a result of delay in seeking care and delay in appropriate and timely referral to the retina surgeon, since there are fewer retina surgeons in this low resource setting. Financial handicap is also a likely reason for this late presentation. Reported studies on barriers to cataract surgical services in Africa have shown that barriers related to awareness and access were more commonly reported. Also there have been reports of cost as the most common barrier [12]. These same barriers can be extrapolated to retina services in Africa as well.

The increased surface area of exposure of the RPE to the vitreous cavity consequent to the giant tear and subsequent migration and proliferation of the RPE cells provide the necessary environment for PVR formation [13] [14]. This situation is further aggravated by patient delay in presentation to the clinic as has already been discussed above. Considering the high rate of PVR, which on its own is a poor prognostic factor for visual and surgical success and the observation in this study that close to half of the patients at presentation were clinically blind in the fellow eyes, one can conclude that patients with this giant retina tear presentation are at high risk of being bilaterally blind. This therefore presents considerable challenge to the patient and his or her family, surgeon and the community.

As shown in **Figure 1**, the fellow eyes of these patients were eventful with most of them (16; 44%) being blind at presentation. Vision in these blind eyes was hand motion, perception of light or no light perception. It is possible that some of these eyes may have lost vision from an untreated retina detachment. Twelve (33%) had received prophylactic retina laser to peripheral retina predisposing lesions. Only a minority of eyes (5; 14%) was classified as normal. Three eyes had a recent retina detachment in the fellow eyes.

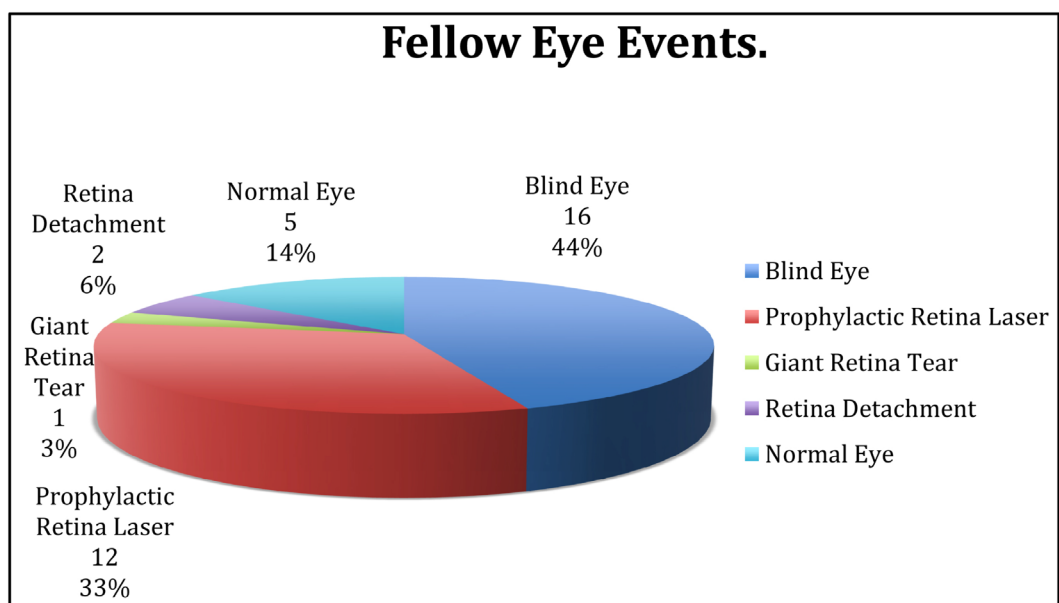


Figure 1. Showing fellow eye events.

Prophylactic retina treatment to the contralateral eye of retina detachment eyes has been a controversial topic. There have been studies showing benefit of this treatment while others question the value of this practice [15] [16] [17]. In the light of the findings of this study, in which a majority of the fellow eyes have significant adverse events, one can justify the position that for the situation in poor resource countries prophylactic treatment to the contralateral eye ought to be pursued more aggressively for whatever benefit it may offer in preserving the fellow eyes. All be it, it remains true that prospective studies with adequate sample size and long term follow up will be required to confirm the validity of such prophylactic treatment [16]. This study did not consider the role of systemic diseases such as Marfans disease, which are well established causes of bilateral GRT.

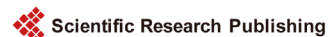To conclude, this study is the first review of a series of exclusive GRT from a black African population. It confirms that GRT detachment presents as a complex situation with significant PVR and poor preoperative vision. The reasons for this may be related to access to vitreoretina service and other socioeconomic reasons. Much work has to be done to create awareness and improve access to vitreoretina services within sub Saharan Africa.

References

- [1] Machemer, R. and Allen, A.W. (1976) Retinal Tears 180 Degrees and Greater. Management with Vitrectomy and Intravitreal Gas. *Archives Ophthalmology*, **94**, 1340-1346. <https://doi.org/10.1001/archophth.1976.03910040212014>
- [2] Michels, R.G. (1979) Vitrectomy Techniques in Retinal Reattachment Surgery. *Ophthalmology*, **86**, 556-585. [https://doi.org/10.1016/S0161-6420\(79\)35485-9](https://doi.org/10.1016/S0161-6420(79)35485-9)
- [3] Ambresin, A., Wolfensberger, T.J. and Bovey, E.H. (2003) Management of Giant Retinal Tears with Vitrectomy, Internal Tamponade, and Peripheral 360 Degrees Retinal Photocoagulation. *Retina*, **23**, 622-628. <https://doi.org/10.1097/00006982-200310000-00003>
- [4] Sherif, A.D. (2014) The Outcome of Surgical Management for Giant Retinal Tear More Than 180°. *BMC Ophthalmology*, **14**, 86. <https://doi.org/10.1186/1471-2415-14-86>
- [5] Shunmugam, M., Ang, G.S. and Lois, N. (2014) Giant Retina Tears. *Survey of Ophthalmology*, **59**, 92-216. <https://doi.org/10.1016/j.survophthal.2013.03.006>
- [6] Ghee, S.A., John, T. and Noemi, L. (2010) Epidemiology of Giant Retinal Tears in the United Kingdom: the British Giant Retinal Tear Epidemiology Eye Study (BGEES). *Investigative Ophthalmology & Visual Science*, **51**, 4781-4787. <https://doi.org/10.1167/iovs.09-5036>
- [7] Mitry, D., Singh, J., Yorston, D., Siddiqui, M.A.R. and Wright, A. (2011) The Pre-disposing Pathology and Clinical Characteristics in the Scottish Retinal Detachment Study. *Ophthalmology*, **118**, 1429-1434.
- [8] Yorston, D.B., Wood, M.L. and Gilbert, C. (2002) Retinal Detachment in East Africa. *Ophthalmology*, **12**, 2279-2283. [https://doi.org/10.1016/S0161-6420\(02\)01284-8](https://doi.org/10.1016/S0161-6420(02)01284-8)
- [9] Yorston, D. and Jalali, S. (2002) Retinal Detachment in Developing Countries. *Eye*, **16**, 353-358. <https://doi.org/10.1038/sj.eye.6700188>
- [10] Chang, S., Lincoff, H., Zimmerman, N.J., *et al.* (1989) Giant Retinal Tears: Surgical Techniques and Results Using Perfluorocarbon Liquids. *Arch Ophthalmology*, **107**,

761-766. <https://doi.org/10.1001/archophth.1989.01070010779046>

- [11] Kertes, P.J., Wafapoor, H., Peyman, G.A., Calixto Jr., N., Thompson, H. and Vitreous Collaborative Study Group (1997) The Management of Giant Retinal Tears Using Perfluoroperhydrophenanthrene: A Multicenter Case Series. *Ophthalmology*, **104**, 1159-1165. [https://doi.org/10.1016/S0161-6420\(97\)30168-7](https://doi.org/10.1016/S0161-6420(97)30168-7)
- [12] Aboobaker, S. and Courtright, P. (2016) Barriers to Cataract Surgery in Africa: A Systematic Review. *Middle East African Journal of Ophthalmology*, **23**, 145-149. <https://doi.org/10.4103/0974-9233.164615>
- [13] Bonnet, M. (1984) Clinical Factors Predisposing to Massive Proliferative Vitreoretinopathy in Rhegmatogenous Retinal Detachment. *Ophthalmologica*, **188**, 148-152. <https://doi.org/10.1159/000309357>
- [14] Girard, P., Mimoun, G., Karpouzas, I. and Montefiore, G. (1994) Clinical Risk Factors for Proliferative Vitreoretinopathy after Retinal Detachment surgery. *Retina*, **14**, 417-424. <https://doi.org/10.1097/00006982-199414050-00005>
- [15] Freeman, H.M. (1978) Fellow Eyes of Giant Retinal Breaks. *Transactions of the American Ophthalmological Society*, **76**, 343-382.
- [16] Wolfensberger, T.J., Aylward, W. and Leaver, P.K. (2003) Prophylactic 360° Cryotherapy in Fellow Eyes of Patients with Spontaneous Giant Retinal Tears. *Ophthalmology*, **10**, 1175-1177. [https://doi.org/10.1016/S0161-6420\(03\)00256-2](https://doi.org/10.1016/S0161-6420(03)00256-2)
- [17] Mastropasqua, L., Carpineto, P., Ciancaglini, M., Falconio, G. and Gallenga, P.E. (1999) Treatment of Retinal Tears and Lattice Degenerations in Fellow Eyes in High Risk Patients Suffering Retinal Detachment: A Prospective Study. *British Journal of Ophthalmology*, **83**, 1046-1049. <https://doi.org/10.1136/bjo.83.9.1046>



Submit or recommend next manuscript to SCIRP and we will provide best service for you:

Accepting pre-submission inquiries through Email, Facebook, LinkedIn, Twitter, etc.

A wide selection of journals (inclusive of 9 subjects, more than 200 journals)

Providing 24-hour high-quality service

User-friendly online submission system

Fair and swift peer-review system

Efficient typesetting and proofreading procedure

Display of the result of downloads and visits, as well as the number of cited articles

Maximum dissemination of your research work

Submit your manuscript at: <http://papersubmission.scirp.org/>

Or contact ojoph@scirp.org