



# Analysis of Radiographic Signs to Predict the Risk of Damage to the Inferior Alveolar Nerve Following Impacted Mandibular Third Molar Extraction among Sinhalese Population

L. H. M. I. M. Herath<sup>1\*</sup>, S. Padma Silva<sup>2</sup> and A. Dharmapala<sup>3</sup>

<sup>1</sup>Department of Radiography & Radiotherapy, Faculty of Allied Health Sciences, General Sir John Kotelawala Defence University, 10290, Sri Lanka.

<sup>2</sup>Oral and Maxillofacial Surgeon, Oral and Maxillofacial Surgery Unit, National Dental Teaching Hospital, Ward Place, 00700, Sri Lanka.

<sup>3</sup>Department of Radiology, National Dental Teaching Hospital, Ward Place, 00700, Sri Lanka.

## Authors' contributions

This work was carried out in collaboration among all authors. Author LHMIMH designed the study, performed the statistical analysis, wrote the protocol and wrote the manuscript. Author SPS read the images and supervised the study. Author AD managed the data collection. All authors read and approved the final manuscript.

## Article Information

### Editor(s):

(1) Dr. João Paulo Schwartz, Paulista State University, Brazil.

### Reviewers:

(1) Ali Azhar Dawasaz, King Khalid University, Saudi Arabia.

(2) Santosh R. Patil, New Horizon Dental College and Research Institute, India.

Complete Peer review History: <http://www.sdiarticle4.com/review-history/64929>

Received 24 November 2020

Accepted 29 January 2021

Published 23 February 2021

Original Research Article

## ABSTRACT

**Aims:** This study aimed to define the panoramic criteria that can be used in predicting the direct contact between impacted mandibular third molar (MTM) and the inferior alveolar nerve (IAN).

**Study Design:** A prospective cross-sectional study.

**Place and Duration of Study:** This study was carried out at Unit B in National Dental Teaching Hospital, Ward Place, Colombo 07 from July 2019 to February 2020.

**Methodology:** Both orthopantomography (OPG) and cone beam computed tomography (CBCT) images of 107 impacted MTMs were assessed to record the radiographic signs for each impacted tooth. The angulation and the position of impaction, Rood & Shehab signs including superimposition, mandibular canal (MC) position relative to the MTM roots, proximity of MTM roots

to MC, and the changes of cortical plates due to impacted MTM roots were recorded with sex and age. The Chi-square and Fishers' exact tests were used for comparison.

**Results:** The most common position of impaction was position B, most common impaction angulation was mesial angulation, most common OPG sign was interruption of white line, and most common MC position was lingual position relative to the MTM roots. Position A, and position B, A-vertical impaction type, B-horizontal impaction type, darkening of roots, sign combinations of darkening and superimposition, and darkening and interruption, and lingually located MC relative to the MTM roots were significantly correlated with direct contact between impacted MTM and the MC ( $P<0.05$ ). The signs of superimposition and narrow root were significantly correlated with lingually positioned MCs ( $P<0.05$ ). The sign of darkening of roots was significantly correlated with lingual and buccal cortical plates thinning ( $P<0.05$ ).

**Conclusion:** With superimposition and darkening or darkening and interruption, or B-horizontal type of impaction, there is a risk of IAN damage during the surgical removal of impacted MTM. With A-vertical type of impaction, there was no risk of damage to IAN. The sign combination of superimposition and darkening has a high positive predictive value for predicting contact MTM roots to MC than buccal plate thinning.

*Keywords: Radiographic signs; orthopantomography; cone beam computed tomography; mandibular third molar; inferior alveolar nerve.*

## 1. INTRODUCTION

Mandibular third molars (MTMs), which are located most posteriorly in the mandible, exist in 90% of the general population, with 33% having at least one impacted MTM [1]. According to the Winter's classification there are seven main types of impactions can be found related to the MTM such as mesioangular, distoangular, vertical, horizontal, buccoangular, linguoangular and inverse [2]. According to Pell & Gregory classification, the impacted MTM can be classified as two main ways such as Class and Position. Class I, Class II and Class III are based on the relation of the impacted MTM to anterior ramus of the mandible and the second molar. Position A, Position B and Position C are based on the relative depth of the impacted tooth in the mandible [3].

Recent studies have reported that impacted third molars might cause a series of complications such as caries, germination disorders, repeated episodes of pericoronitis, periodontal lesions of the second molar, orthodontic problems, and even follicular cysts. Considering the massive complications caused by impacted third molars, surgical removal of them may be the best option. However, most patients complain about discomfort after surgery such as swelling, pain, bleeding, trismus, dry socket, dehiscence during primary wound healing, or even numbness of the lower lip (paresthesia) caused by inferior alveolar nerve (IAN) injury [1].

Several studies have reported that the incidence of IAN injury is between 0.4% to 8.4%, with no

recovery from the injury reported in approximately 0.12% to 0.30% of cases. Some research shows that there is a 15-25% increased risk of preoperative paresthesia following IAN exposure, and this may be temporary or permanent in nature. Permanent paresthesia may lead to functional compromise and a decreased quality of life. The spatial relationship between the MTM root and the mandibular canal (MC) is the most predictable risk factor for IAN injury [1]. Therefore, it is vital for surgeons to understand the relationship between the MTM and the MC wall defect before surgery, which might help inform IAN damage risk assessment and surgical operation planning, as well as risk communication with patients before surgery.

The periapical radiography and orthopantomography (OPG) are the most used clinical X-ray examinations to assess the risk factors for IAN injury in dentistry [1]. But OPG is the standard imaging technique performed before MTM extraction to assess the risk factors [4]. Specific radiographic signs have been identified by Rood and Shehab on panoramic images that may suggest a close relationship between MTM, and the MC. These radiographic signs include interruption of the superior radiopaque white line of the MC, darkening of the tooth roots, narrowing of the tooth root, deflection of the tooth roots, bifid root apices, narrowing of the canal, and deviation of the canal [5].

But OPG does not provide any information regarding the buccolingual dimension of MC with respect to the impacted MTM roots. Assessment of buccolingual dimension of MC

relative to the impacted tooth roots is important in predicting risk of IAN damage during surgical removal of impacted MTM since the nature of risk can be varied with buccolingual position of MC, and the buccolingual position of the MC is associated with age and race [4]. In these cases, cone beam computed tomography (CBCT) is recommended, and some research shows that CBCT is highly accurate imaging modality than OPG in predicting risk of IAN injury since it demonstrates the true contact of impacted MTM roots to MC (IAN exposure) [6,7]. Moreover, some research reveals that relying on OPG signs is not acceptable since darkening of roots can be seen not only due to the IAN exposure, but also due to the buccal or lingual cortical plate thinning or perforation by tooth roots [6,8,9]. These changes occur in the cortical plates can be seen only on CBCT images.

Although CBCT offers better image quality, it carries a higher exposure dose than OPG. Furthermore, CBCT is less available in certain areas, and its higher cost considering the socioeconomic situations of some developing countries justify the use of OPG alone in the preoperative assessment of impacted MTM [1]. Therefore, it is important to have a correlation between OPG sign and CBCT signs can be used to predict the risk of IAN damage when only an OPG image is assessed. The researchers recently have found that some correlations, but dental practitioners in Sri Lanka cannot use those relationships due to the dependency of buccolingual course of MC on ethnicity. The present study was planned based on this requirement and therefore, the results of this study will help Sri Lankan dental surgeons to predict the IAN exposure before planning the surgical removal of impacted MTM.

## 2. METHODOLOGY

The present study was carried out as a prospective study at Unit B in National Dental Teaching Hospital, Ward Place, Colombo 07. All the patients, having one or both impacted MTM who attended the Oral and Maxillofacial Surgery - Unit B in National Dental Teaching Hospital during the period of data collection from July 2019 to February 2020 were selected as the study population.

The convenient sampling method was used, and the population was assessed against the inclusion and exclusion criteria of the study to select the study sample. The patients who had

one or both impacted MTM to be surgically removed, the patients who had a close proximity between MC and roots of impacted MTM diagnosed from preoperative panoramic image and followed by CBCT examination, the patients who had completely developed MTM roots, and the patients who were in the age group of 17-35 years of age were included to the study sample. Most of the patients who came to do the impacted third molar extraction surgery were in this age group. The patients who were not Sinhalese, and the patients had mandibular lesions such as cysts, osteomyelitis, tumors around the MC and MTM were excluded from the study.

The total of 66 patients, including 28 males and 38 females were selected as the study sample. CS (care stream) 9300 3D panoramic machine (USA) was operated at 70 kVp, 12 mA, and 15.3 s for OPG examinations, and operated at 90 kVp, 6.3 mA, and 11.3 s with the slice thickness of 1mm for CBCT examinations. The digital versatile discs (DVDs) were used to copy the OPG and CBCT images. CS imaging software was used to read the OPG and CBCT images to collect the data. The data were entered in an Excel sheet and collected data will be discarded after two years. IBM Statistical Package for the Social Sciences (SPSS) 20 version for Windows. The probability values less than 0.05 were considered statistically significant in all statistical testing.

The OPG and CBCT examinations were done by well experienced and qualified radiological technologists and, OPG and CBCT images were copied into DVDs once a month. The total number of 107 impacted MTMs (42 impacted teeth from males and 65 impacted teeth from females) were examined by two experienced dental surgeons. The OPG images were read first and relevant CBCT images were evaluated at two-week intervals. The side of the impacted tooth, level of impaction according to the Pell & Gregory classification (position A, B, and C), angulation of impaction according to the Winter's classification (mesially, distally, vertically, horizontally, buccally, and lingually), and absence or presence of Rood & Shehab's predictor signs including superimposition were recorded from each OPG image. The position of the MC relative to the MTM roots (buccal/lingual/inferior/interradicular), proximity of MTM roots to the MC (contact/separate), corticalization of lingual and buccal plates (complete plate/thinned plate/perforated plate),

age and, the gender were recorded from each CBCT image.

All data were coded and analyzed using IBM statistical package for the social sciences (SPSS) 20 version and the probability values less than 0.05 were considered statistically significant in all statistical testing. The kappa coefficient (k) values were calculated for OPG and CBCT findings to measure the inter-observer agreement. The k value of 0.01-0.20 was considered as slight agreement, 0.21-0.40 was fair agreement, 0.41-0.60 was moderate agreement, 0.61-0.80 was substantial agreement, and 0.81-1.00 was almost perfect agreement (Viera & Garrett, 2005; Landis & Koch, 1977). Pearson's chi-square test and Fisher's exact test were applied with post hoc analysis to assess the correlations.

### 3. RESULTS AND DISCUSSION

The present study incorporated 107 impacted MTMs including 54 right and 53 left impacted teeth from 66 patients (28 males and 38 females, age range of 17-35 years) who attended Unit B at National Dental Teaching Hospital, Colombo. The percentage of impacted MTMs in position A, B, and C are illustrated in Fig. 1. The impaction angulations were considered as mesially, distally, vertically, horizontally, buccally, and lingually. The distribution of angulation of impacted MTM is given in Fig. 2.

Further, the position and the angulation of impacted MTM was considered as the type of impaction. The distribution of type impaction among Sinhalese population is illustrated in Fig. 3.

Moreover, the OPG signs defined by Rood and Shehab including superimposition of roots over MC were considered. The distribution of Rood and Shehab's radiographic signs including superimposition among Sinhalese population is given in Fig. 4. In the present study, no cases were found with only a single OPG sign and all the cases were reported with two or more signs.

When considering the assessment of OPG on combination of these radiographic signs, the distribution of combination of OPG signs among Sinhalese population was resulted as illustrated in Fig. 5.

The MC position relative to the MTM roots were taken as buccally, lingually, inferiorly, and interradiarily. As determined on CBCT images, the distribution of position of MC relative to the impacted MTM roots among Sinhalese population is resulted as given in Fig. 6. Moreover, the distribution of proximity of the impacted MTM roots to the MC among Sinhalese population is illustrated in Fig. 7. When all the changes occurred in lingual and buccal cortical plates were made by the impacted MTM roots were considered, the distribution of nature of lingual and buccal cortical plates among Sinhalese population was resulted as given in Fig. 8.

The kappa (k) values were calculated for interobserver agreement. Interobserver agreement was high for the OPG signs, showing a k value of 0.921 for superimposition, 0.981 for darkening, 0.943 for interruption, 0.828 for narrow root, 0.783 for root deflection, 1.000 for bifid root, 0.921 for narrow canal, 1.000 for canal diversion, 1.000 for position of impacted teeth, and 1.000 for angulation of impaction. Moreover, interobserver agreement was high for CBCT findings too, showing a k value of 0.930 for MC position, 0.829 for proximity of impacted tooth to MC, 0.836 for lingual cortical plate perforation, 1.000 for lingual cortical plate thinning, 1.000 for buccal plate perforation, and 1.000 for buccal plate thinning.

When the relationship between position of the impacted teeth and the proximity of impacted teeth roots to the MC is analyzed (Table 1), there was a strong positive statistical correlation between the position B impacted MTMs and the direct contact of MTM roots to the MC ( $P=0.035$ ; Chi square test). Here, 90.7% (49) of position B impacted MTMs had direct contact with MC, and with a strong negative statistical significance ( $P=0.014$ ; Chi square test), 40.4% (36) of cases having contacted MTM roots with MC showed position A impacted MTMs.

When all the possible types of impaction related to the position A and B are analyzed with the proximity of tooth roots to the MC (Table 2), B-horizontal showed a positive statistically significant correlation with the proximity of MTM roots to MC ( $P=0.043$ ; Chi square test), and A-vertical showed a strong negative statistically significant correlation with the proximity of MTM roots to MC ( $P=0.009$ ; Chi square test).

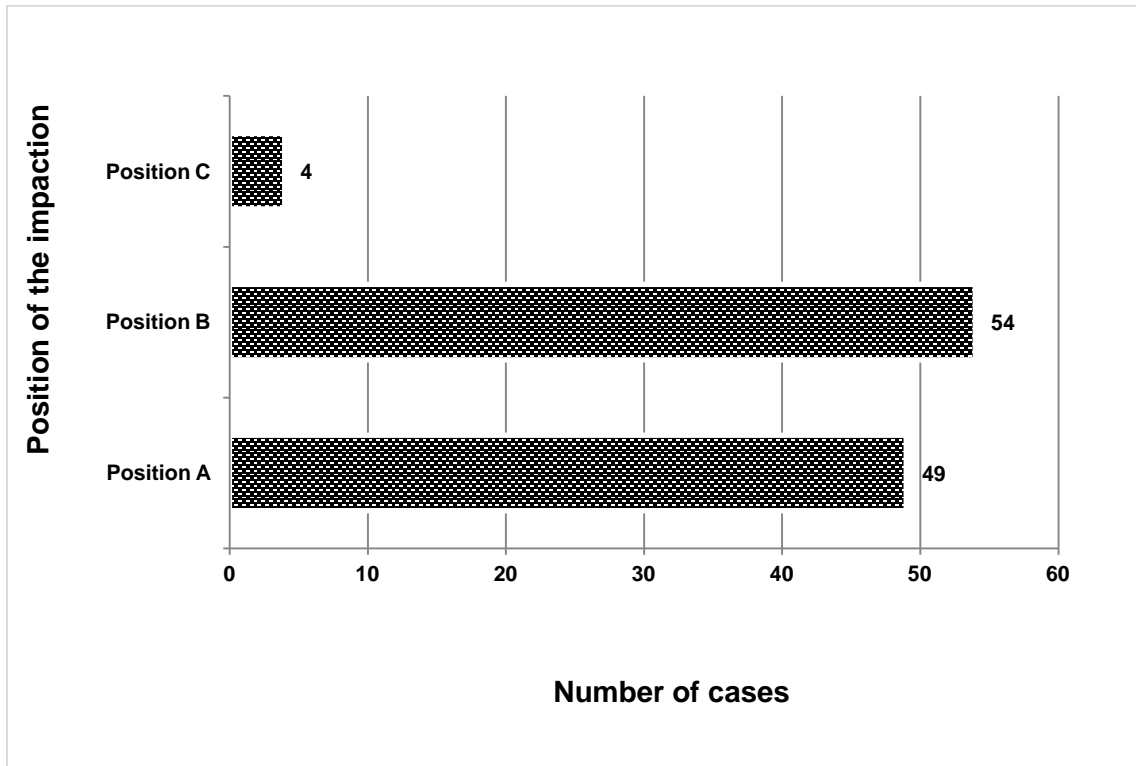


Fig. 1. Distribution of position of impacted MTMs among sinhalese population

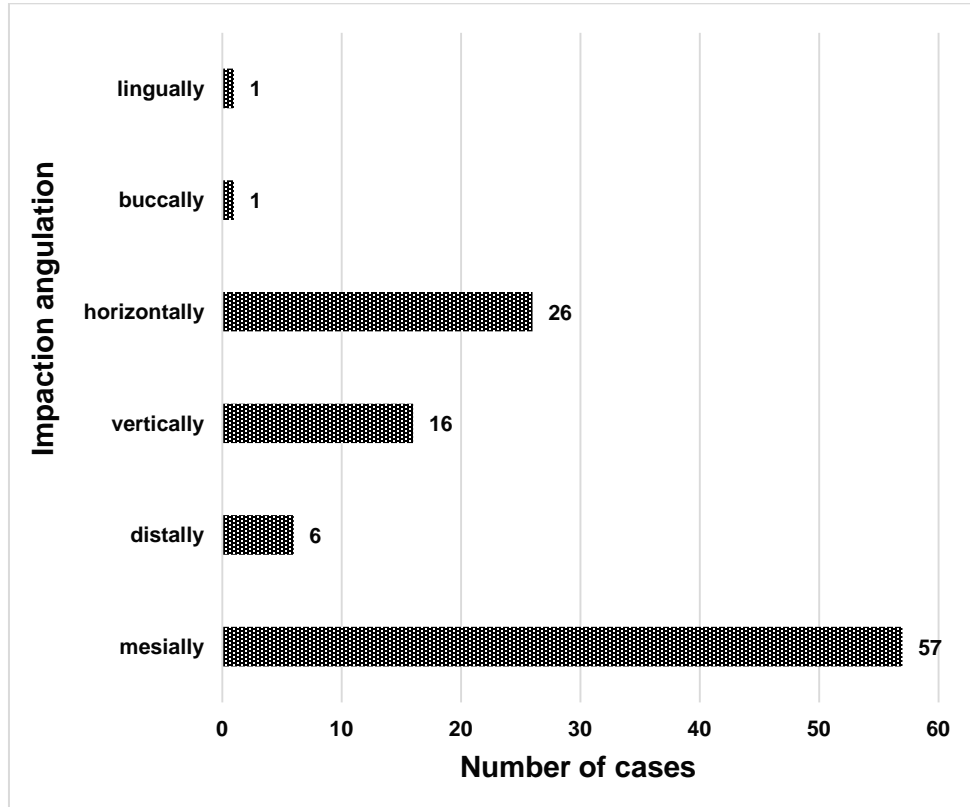


Fig. 2. Distribution of angulation of impacted MTMs among sinhalese population

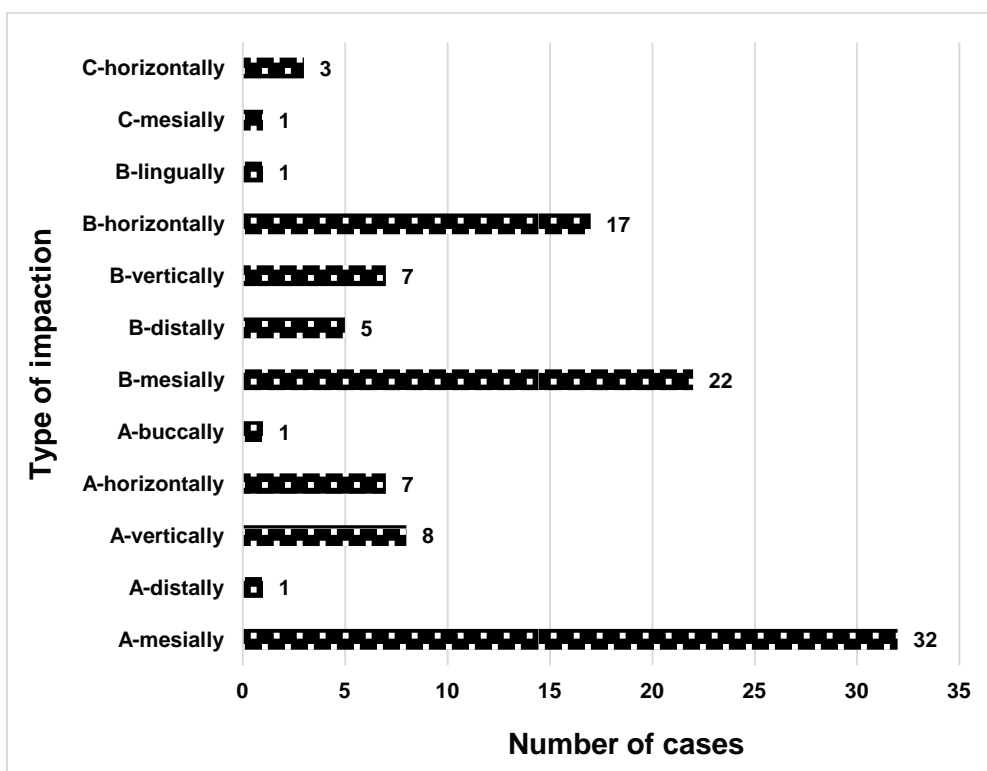


Fig. 3. Distribution of type of impaction among sinhalese population

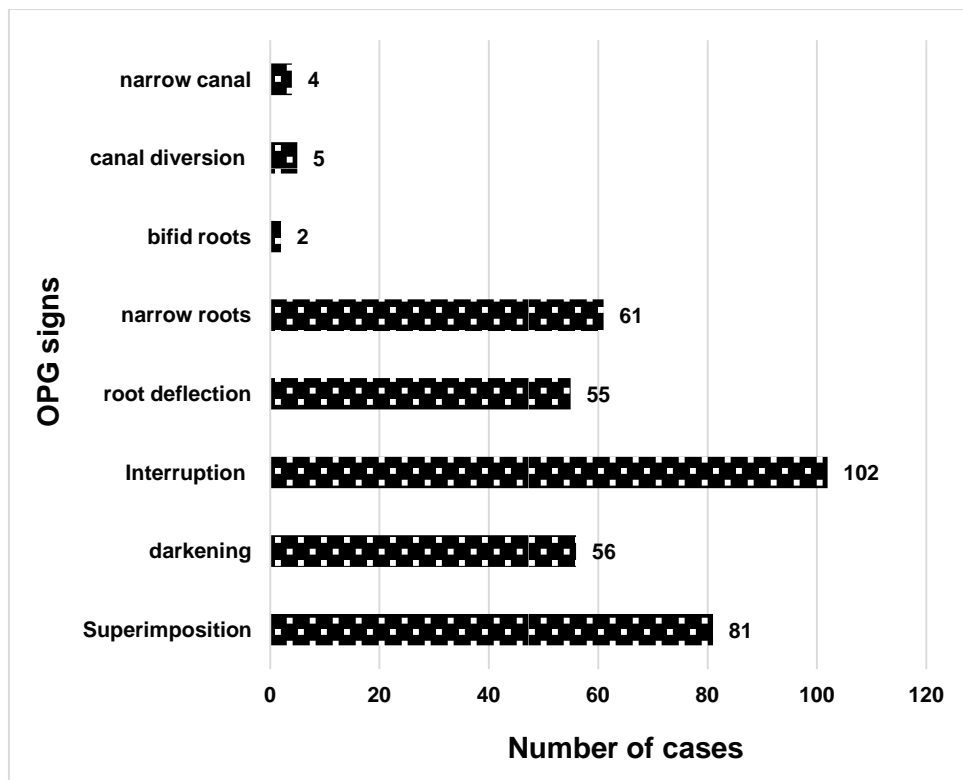


Fig. 4. Distribution of Rood and Shehab's radiographic signs including superimposition among Sinhalese population

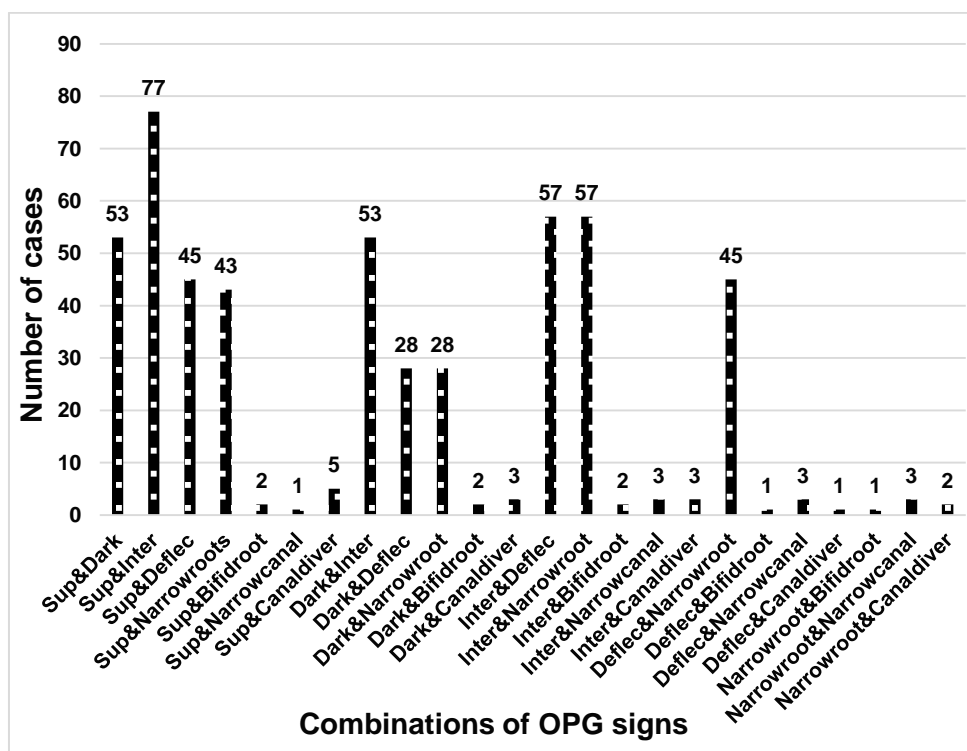


Fig. 5. Distribution of combination of OPG signs among sinhalese population

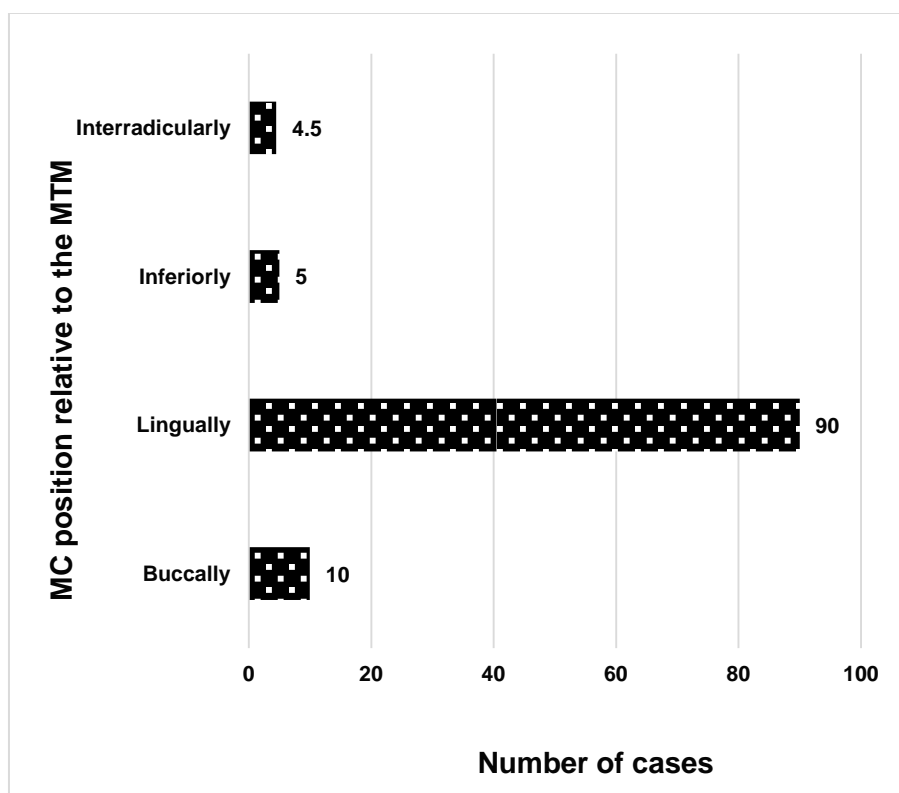
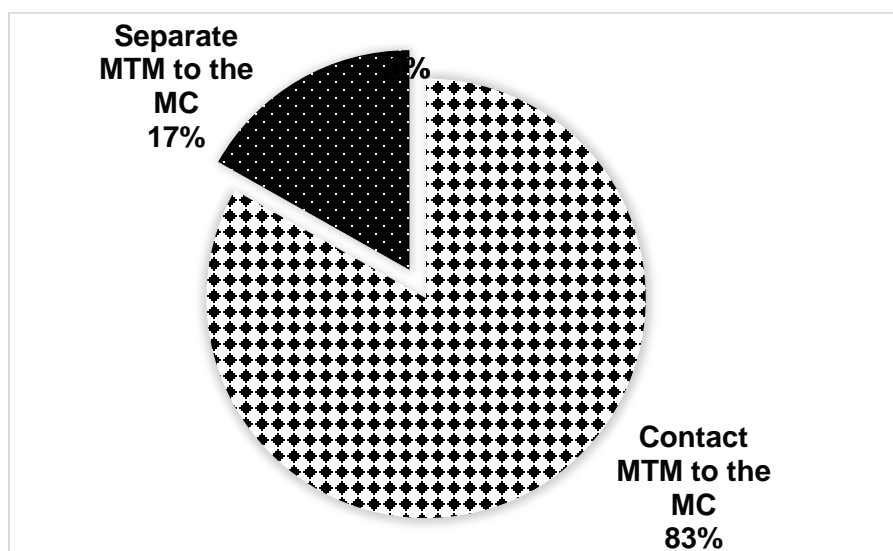
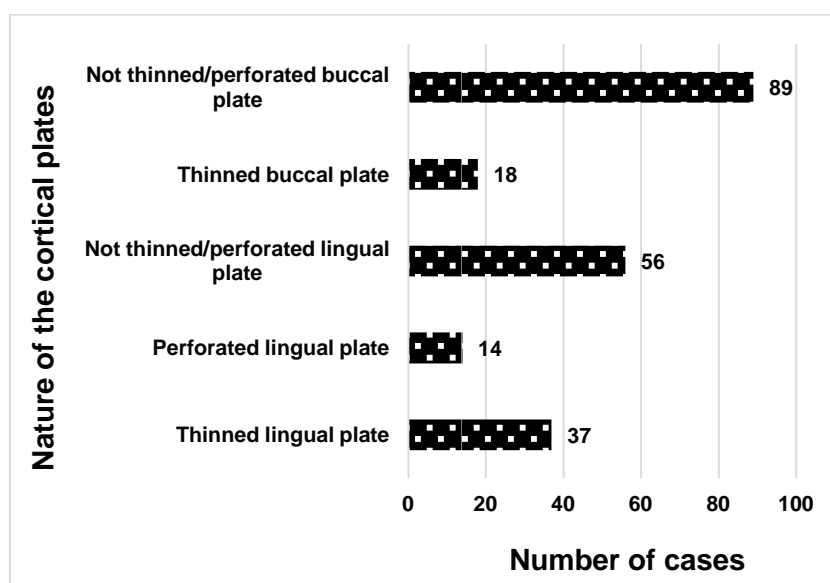


Fig. 6. Distribution of position of MC relative to the impacted MTM roots among sinhalese population



**Fig. 7. Distribution of proximity of the impacted MTM roots to the MC among sinhalese population**



**Fig. 8. Distribution of nature of lingual and buccal cortical plates among sinhalese population**

When all the OPG signs defined by Rood & Shehab including superimposition of MTM roots with MC are analyzed with the proximity of impacted MTM roots to the MC (Table 3), with a strong positive statistical significance ( $P=0.022$ ; Chi square test), 91% (51) of impacted MTMs showing darkening of roots had a direct contact with the MC.

When all the possible combinations of OPG signs are analyzed to evaluate the relationship with the proximity of tooth roots to the MC, superimposition and darkening sign combination

showed a positive statistically significant correlation with the proximity of MTM roots to MC. Here, 90.6% (48) of impacted MTMs showing superimposition and darkening had contacted roots with MC ( $P=0.043$ ; Chi square test). Moreover, darkening of roots and interruption of superior white line sign combination showed a positive statistically significant correlation with the proximity of MTM roots to MC. Here also, 90.6% (48) of impacted MTMs having darkened of roots and interruption of superior white line combination showed a direct contact with MC. The predictive values,



sensitivity, and specificity of the OPG findings which had a positive correlation with contact tooth root to MC are given in Table 4.

When the MC position related to the MTM roots is analyzed with the proximity of tooth roots to the MC (Table 5), the lingually positioned MC showed a strong positive statistically significant correlation with the proximity of MTM roots to MC ( $P=0.026$ ; Chi square test), and the buccally positioned MC showed a strong negative statistically significant correlation with the proximity of MTM roots to MC ( $P=0.003$ ; Chi square test).

When the positions of MC which showed a statistically significant correlation with the proximity of MTM roots to the MC were analyzed with the OPG signs defined by Rood & Shehab including superimposition (Table 6), the lingually positioned MC showed a positive statistically significant correlation with the impacted MTMs having narrow roots ( $P=0.049$ ; Chi square test), and the lingually positioned MC showed a strong negative statistically significant correlation with the impacted MTMs having superimposition of MTM roots with the MC ( $P=0.011$ ; Chi square test).

When the cases having buccally and lingually positioned MC were analyzed with all possible combinations of OPG signs, the buccally positioned MC showed a strong positive statistically significant correlation with the sign combination of superimposition and interruption ( $P=0.038$ ; Chi square test). Here, all the cases having buccally positioned MC showed the sign combination of superimposition and interruption. Moreover, the lingually positioned MC showed a strong negative statistically significant correlation with the sign combination of superimposition and interruption ( $P=0.027$ ; Chi square test). Here, 67.8% (61) of cases having lingually positioned MC had this sign combination. Also, the lingually positioned MC showed a strong positive statistically significant correlation with the sign combination of interruption and narrow roots ( $P=0.007$ ; Chi square test). Here, 93% (53) of cases showing this sign combination had lingually positioned MC. Further, the buccally positioned MC showed a strong negative statistically significant correlation with the sign combinations of interruption and narrow root, and root deflection and narrow roots ( $P=0.027$ ; Chi square test and  $P=0.031$ ; Chi square test). Here, only 3.5% (2) of cases showing sign combination of interruption and narrow roots had buccally

positioned MC while only 2.2% (1) of cases showing sign combination of root deflection and narrow roots had buccally positioned MC.

When the relationship between OPG signs and the changes of lingual cortical plate made by the impacted MTM roots was evaluated (Table 7), the impacted MTMs showing darkening of roots showed a strong negative statistically significant correlation with thinned lingual cortical plate by the MTM roots ( $P=0.029$ ; Chi square test).

When the changes made by MTM roots to the lingual cortical plate were analyzed with all the possible combinations of OPG signs, the sign combination of superimposition and darkening showed a strong negatively significant correlation with thinned lingual cortical plate ( $P=0.01$ ; Chi square test). Here, 22.6% (12) of cases showing the sign combination of superimposition and darkening had a lingual cortical plate which was thinned by MTM roots. When the changes of buccal cortical plate made by the impacted MTM roots were assessed with the combinations OPG signs, the sign combinations of sup. & darkening, sup. & bifid root apex, darkening and bifid root apex showed a strong positively significant correlation with thinned buccal cortical plate ( $P=0.027$ ; Fisher's exact test). The predictive values, sensitivity, and specificity of the OPG findings which had a positive correlation with thinned buccal cortical plate by impacted MTM roots are given in Table 8.

In concordance with a previous study [2], the present study found that a higher incidence of impaction of MTM could be seen with females than males. This may be due to the present study was conducted only at one unit in one hospital among three hospitals which have CBCT facility in Sri Lanka. In concordance with the present study, many researchers [10,11,12] have concluded that the position B was the most common level of eruption within their study sample. In contrast, some researchers [1] have found that the impacted MTMs positioned in high level (position A) in the mandible were more prevalent in their study population. This may be due to large sample size and a wider age range from 18-78 with the mean age of 40.26 years used in their study.

In concordance with the present study, some researchers [13] found IAN damages which led to temporary numbness of the ipsilateral half of the lower lip were more likely found with the MTMs impacted in position B. In contrast,

some studies [1] have concluded that third molars positioned in the low level in the mandible (position C) were more likely to have defective MC. In concordance with the present study, most of the similar studies [4,11,12,14,15] revealed that mesioangular impaction was the most common pattern of third molar impaction in considering the impacted angulation. In contrast, some studies [10,16,17,18] revealed that horizontal impaction was the prevalent pattern of MTM impaction. Further, some authors [1,19,20] found that vertical impaction was the most common pattern of MTM impaction. These disagreements may be due to the representation of less or no diverse range of ethnic groups within the study population.

A similar study [21] replicates our results by saying that third molar angulation was not associated with risk for IAN injury. In contrast,

some of the studies [1,13,19,20,22] reported that horizontal impaction had contacted roots with the IAN bundle due to the defects on MC wall by teeth roots. The reasons for this difference of results might be due to the wide age range used and the large number of study participants involved in the other studies when compared with the present study.

In concordance with the present study, most of the researchers [1,4,16,18,19,21,22,23,24] found that interruption of superior cortical margin of MC was seen in the majority of impacted teeth. In contrast, some studies [5,6,7,8] revealed that darkening of the roots was the most frequent OPG sign appeared in impacted teeth. This may be attributed to the wide age range used and the difference in number of MTMs assessed in these studies rather than in the present study.

**Table 1. The relationship between the position of impacted MTM and the proximity of tooth roots to MC**

	Contact		Separate		Total (N)
	N	%	N	%	
Position A	36*	73.5	13	26.5	49
Position B	49**	90.7	05	9.3	54
Position C	04	100	00	-	04
Total	89	83.2	18	16.8	107

\*  $\chi^2$  value = 6.089, P=0.014, df = 1

\*\*  $\chi^2$  value = 4.457, P=0.035, df = 1

**Table 2. The relationship between type of impaction and MTM roots' proximity to MC**

	Contact		Separate		Total (N)
	N	%	N	%	
A-mesial	25	78.1	7	21.8	32
A-distal	01	100	00	-	01
A-vertical	04*	50	4	50	08
A-horizontal	05	71.4	02	28.5	07
A-buccal	01	100	00	-	01
B-mesial	21	95.4	03	12.5	24
B-distal	04	80	01	20	05
B-vertical	06	85.7	01	14.2	07
B-horizontal	17**	100	00	-	17
B-lingual	01	100	00	-	01
C-mesial	01	100	00	-	01
C-horizontal	03	100	00	-	03
Total	89	83.2	18	16.8	107

\*  $\chi^2$  value = 6.802, P=0.009, df = 1

\*\*  $\chi^2$  value = 4.088, P=0.043, df = 1

**Table 3. The relationship between OPG signs and MTM roots' proximity to MC**

		Contact		Separate		Total (N)
		N	%	N	%	
Superimposition of roots on MC (Sup.)	Yes	70	86.4	11	13.6	81
	No	19	73.1	07	26.9	26
Darkening of roots (Dark.)	Yes	51	91.1	05	8.9	56
	No	38	74.5	13	25.5	51
Interruption of white line (Inter.)	Yes	85	83.3	17	16.7	102
	No	04	80	01	20	05
Deflection of roots (Deflec.)	Yes	45	81.8	10	18.2	55
	No	44	84.6	08	15.4	52
Narrow roots (Na.roots)	Yes	50	82	11	18	61
	No	39	84.8	07	15.2	46
Bifid roots (Bi.roots)	Yes	02	100	00	-	02
	No	87	82.9	18	17.1	105
Narrow canal (Na.canal)	Yes	04	100	00	-	04
	No	85	82.5	18	17.5	103
Canal diversion (Canal di.)	Yes	04	80	01	20	05
	No	85	83.3	17	16.7	102
Total		89	83.2	18	16.8	107

$$\chi^2 \text{ value} = 5.232, P=0.022, df = 1$$

**Table 4. Predictive values, sensitivity, and specificity of the OPG findings which had a positive correlation with contact tooth root to MC**

OPG finding	Positive predictive value (PPV)	Negative predictive value (NPV)	Sensitivity	Specificity
Darkening of roots	0.910	0.25	0.57	0.72
Sup. & Dark.	0.906	0.24	0.54	0.72
Dark. & Inter.	0.906	0.24	0.54	0.72
Position B impaction	0.907	0.24	0.55	0.72
B, Horizontal impaction	1.000	0.20	0.19	1.00

**Table 5. The relationship between MC position and MTM roots' proximity to the MC**

	Contact		Separate		Total (N)
	N	%	N	%	
Buccal	5*	5.6	5	27.7	10
Lingual	78**	87.6	12	66.7	90
Inferior	04	4.5	01	5.6	05
Interradicular	02	2.2	00	-	02
Total	89	100	18	100	107

$$\chi^2 \text{ value} = 8.678, P=0.003, df = 1$$

$$\chi^2 \text{ value} = 4.928, P=0.026, df = 1$$

In concordance with the present study most of the previous studies [4,5,16,19,20,21, 22,24,25,26] reported that darkening of tooth root was positively significantly associated with IAN exposure. In concordance with the present study, another previous study done on correlation of panoramic radiographs and cone beam computed tomography in the assessment of a

superimposed relationship between the mandibular canal and impacted third molars [6] revealed that there was a positive statistical correlation between the sign combination of darkening and interruption and contact impacted MTM roots with MC. Similar to the present study, most of the researchers [10,18,20,26] found that the MC was most

commonly located lingually. In contrast, some researchers [1,4,16,23] reported that the MC was predominantly in the inferior position relative to the impacted MTM roots.

Similar to the present study, most of the studies [1,6,10,13,18,23,24,26] found that there was a

statistically significant positive correlation between lingually positioned MC and cortical perforation of MC wall. Even though some other studies [4,6] reported that the panoramic radiographic signs were statistically correlated with the buccolingual position of MC relative to the impacted MTM roots, there were

**Table 6. The relationship between OPG signs and the position of MC relative to the MTM roots**

		Buccal		Lingual		Inferior		Interradicular		Total (N)
		N	%	N	%	N	%	N	%	
Sup.	Yes	10	12.3	64*	79	05	6.2	02	2.5	81
	No	00	-	26	100	00	-	00	-	26
Dark.	Yes	05	8.9	47	83.9	03	5.3	01	1.8	56
	No	05	9.8	43	84.3	02	3.9	01	1.9	51
Inter.	Yes	10	9.8	86	84.3	04	3.9	02	1.9	102
	No	00	-	04	80	01	20	00	-	05
Deflec.	Yes	03	5.5	47	85.4	04	7.3	01	1.8	55
	No	07	13.4	43	82.7	01	1.9	01	1.9	52
Na.roots	Yes	03	4.9	55**	90.2	02	3.3	01	1.6	61
	No	07	15.2	35	76.1	03	6.5	01	2.2	46
Bi.roots	Yes	01	50	01	50	00	-	00	-	02
	No	09	8.6	89	84.8	05	4.7	02	1.9	105
Na.canal	Yes	00	-	04	100	00	-	00	-	04
	No	10	9.7	86	83.5	05	4.8	02	1.9	103
Canal di.	Yes	00	-	05	100	00	-	00	-	05
	No	10	9.8	85	83.3	05	4.9	02	1.9	102
Total		10	9.3	90	84.1	05	4.7	02	1.9	107

\* $\chi^2$  value = 6.488, P=0.011, df = 1  
 \*\* $\chi^2$  value = 3.889, P=0.049, df = 1

**Table 7. The relationship between OPG signs and the nature of the lingual cortical plate**

		Thinned lingual plate		Perforated lingual plate		Complete lingual plate		Total (N)
		N	%	N	%	N	%	
Sup.	Yes	21	25.9	10	12.3	50	61.7	81
	No	16	61.5	04	15.4	06	23.1	26
Dark.	Yes	14*	25	09	16.1	33	58.9	56
	No	23	45.1	05	9.8	23	45.1	51
Inter.	Yes	37	36.3	13	12.7	52	51	102
	No	00	-	01	20	04	80	05
Deflec.	Yes	18	32.5	07	12.7	30	54.5	55
	No	19	36.5	07	13.5	26	50	52
Na.roots	Yes	22	36	09	14.8	30	49.2	61
	No	15	32.6	05	10.8	26	56.5	46
Bi.roots	Yes	00	-	00	-	02	100	02
	No	37	35.2	14	13.3	54	51.4	105
Na.canal	Yes	03	75	00	-	01	25	04
	No	34	33	14	13.6	55	53.4	103
Canal di.	Yes	01	20	01	20	03	60	05
	No	36	35.3	13	12.7	53	51.9	102
Total		37	34.6	14	13.1	56	52.3	107

\* $\chi^2$  value = 4.766, P=0.029, df = 1

**Table 8. Predictive values, sensitivity and specificity of the OPG signs which had a positive association with buccal cortical plate thinning**

OPG sign	Positive predictive value (PPV)	Negative predictive value (NPV)	Sensitivity	Specificity
Sup. & Dark.	0.25	0.94	0.72	0.55
Sup. & Bifid root	1.00	0.84	0.11	1.00
Dark. & Bifid root	1.00	0.84	0.11	1.00
Inter. & Bifid root	1.00	0.84	0.11	1.00

disagreement among studies. According to one of these studies [4], in cases of darkening of roots, and narrowing of the canal, the canal position was inferior to the impacted tooth roots. According to the other study [6], the sign combination of darkening and interruption was positively correlated with buccally positioned MC. These disagreement of results among studies may be due to several reasons including different age ranges used, diverse or less diverse ethnic groups used, difference in number of impacted MTMs assessed, and changes in frequencies of impaction angulation observed among studies.

A study done on correlation of the radiological predictive factors of IAN injury with CBCT findings [8] replicates our results by concluding that darkening of roots evident on the plain films indicates the reduction in the thickness or grooving of either the lingual or buccal cortex by the tooth roots, nerve, or both. Deviation of some of results of the present study from the previous studies may be due to the limitations of the present study. Comparatively small number of impacted MTMs were assessed due to the limitation of data collection period, and limitation of access to other units and the hospitals which have CBCT facility. Further, the present study was not carried out on other ethnic groups available in Sri Lanka, and on different age groups due to the limitation of time.

**4. CONCLUSION**

When one of OPG findings of darkening of roots, superimposition and darkening of roots, darkening of roots and interruption of white line, position B impaction, and B-horizontal type of impaction is seen on the OPG image, there is a risk of IAN damage during the surgical removal of impacted MTM.

When the impacted MTM is in position A or A-vertical type on the OPG image, there is no risk of IAN damage during the surgical removal of impacted MTM. There is a risk of damage to IAN during the surgical removal of impacted MTMs which are positioned buccally to the MC. There is

no risk of damage to the IAN associated with the surgical removal of impacted MTMs which are positioned lingually to the MC.

There is a possibility of having a risk of damage to IAN during the surgical removal of impacted MTMs with the OPG signs of narrowing of roots, or interruption and narrowing of roots combination, or deflection of roots and narrow roots combination. There is no possibility of having a damage to IAN damage during the surgical removal of impacted MTMs with the OPG signs of superimposition, or superimposition and interruption combination.

The lingual cortical plate thinned by impacted MTM roots cannot be seen when darkening of roots, or superimposition and darkening of roots appear on the OPG image. The buccal cortical plate thinned by impacted MTM roots can be seen when the OPG image shows one of the sign combinations of superimposition and darkening of roots, superimposition and bifid roots, darkening of roots and bifid roots, and interruption and bifid roots.

B-horizontal had a higher PPV than other predictor signs in predicting IAN damage. The sign combination of superimposition and darkening of roots reflects both contact impacted MTM roots to the MC, and thinned buccal cortical plate. But this sign combination had a high PPV for contact tooth roots to the MC.

It is highly recommended that the evaluation of OPG signs to predict the risk of damage to IAN during impacted MTM removal should be extended on increased number of cases, different ethnic groups, and different age groups to accurately generalize the results for the Sri Lankan population since these were limitations of the present study.

**CONSENT**

As per international standard or university standard, patient’s written consent has been collected and preserved by the authors.

## ETHICAL APPROVAL

The ethical approval was obtained from the ethical review committee (ERC) of Faculty of Medicine, General Sir John Kotelawala Defence University, and the permission was obtained from the Director, National Dental Teaching Hospital, Ward Place, Colombo 07.

## COMPETING INTERESTS

Authors have declared that no competing interests exist.

## REFERENCES

1. Chen Y, Liu J, Pei J, Liu Y, Pan J. The risk factors that can increase possibility of mandibular canal wall damage in adult: A cone-beam computed tomography (cbct) study in a chinese population. *Med Sci Monit.* 2018; 24:26-36. [PMID: 29293490, DOI: 10.12659/MSM.905475]
2. Santosh P. Impacted mandibular third molars: Review of literature and a proposal of a combined clinical and radiological classification. *Ann Med Health Sci Res.* 2015;5(4):229-34. PMID: 26229709, DOI: 10.4103/2141-9248.160177
3. Pell GJ, Gregory GT. Impacted mandibular third molars; Classification and modified technique for removal. *The Dental Digest.* 1933;39(9):330-8.
4. Elkhateeb M, Awad SS. Accuracy of panoramic radiographic predictor signs in the assessment of proximity of impacted third molars with the mandibular canal. *J Taibah Univ Med Sci.* 2018;13(3):254-61. [PMID: 31435332, DOI: 10.1016/j.jtumed.2018.02.006]
5. Rood JP, Shehab BA. The radiological prediction of inferior alveolar nerve injury during third molar surgery. *Br J Oral Maxillofac Surg.* 1990; 28:20-25. PMID: 2322523 DOI: 10.1016/0266-4356(90)90005-6
6. Jung YH, Nah K, Cho BH. Correlation of panoramic radiographs and cone beam computed tomography in the assessment of a superimposed relationship between the mandibular canal and impacted third molars. *Imaging Sci Dent.* 2012;42(3):121-7. PMID: 23071961, DOI: 10.5624/isd.2012.42.3.121
7. Pandeya R, Ravindran C, Pandiyan D, Gupta A, Aggarwal A, Aryasri S. Assessment of roods and shehab criteria if one or moreradiological signs are present in orthopan-tomogram andposition of the mandibular canal in relation to the third molar apices using cone beam computed tomography: a radiographic study. *Tanta Dent J.* 2018;15(1):33-38. DOI: 10.4103/tdj.tdj\_53\_17
8. Umar G, Bryant C, Obisesan O, Rood JP. Correlation of the radiological predictive factors of inferioralveolar nerve injury with cone beam computed tomography findings. *Oral Surgery.* 2010;3(3):72-82. DOI: 10.1111/j.1752-248X.2010.01088.x
9. Tantanapornkul W, Okochi K, Bhakdinaronk A, Ohbayashi N, Kurabayashi T. Correlation of darkening of impacted mandibular third molar root on digital panoramic images with cone beam computed tomography findings. *Dentomaxillofac Radiol.* 2009;38(1):11–16. PMID: 19114418, DOI: 10.1259/dmfr/83819416
10. Shujaat S, Abouelkheir HM, Al-Khalifa KS, Al-Jandan B, Marei HF. Pre-operative assessment of relationship between inferior dental nerve canal and mandibular impacted third molar in Saudi population. *Saudi Dent J.* 2014;26(3):103-7. [PMID: 25057230, DOI: 10.1016/j.sdentj.2014.03.005]
11. Hassan AH. Pattern of third molar impaction in Saudi population. *Clin Cosmet Investig Dent.* 2010; 2:109-13. [PMID: 23662088, DOI: 10.2147/CCIDEN.S12394]
12. Quek SL, Tay CK, Tay KH, Toh SL, Lim KC. Pattern of third molar impaction in a Singapore Chinese population: a retrospective radiographic survey. *Int J Oral Maxillofac Surg.* 2003;32(5):548-52. PMID: 14759117
13. Ye ZX, Yang C, Abdelrehem A. Prediction of inferior alveolar nerve injury in complicated mandibular wisdom teeth extractions: a new classification system. *Int J Clin Exp Med.* 2016;9(2):3729-34.
14. Syed KB, Zaheer KB, Ibrahim M, Bagi MA, Assiri MA. Prevalence of impacted molar teeth among Saudi population in Asir region, Saudi Arabia- a retrospective study of 3 years. *J Int Oral Health.* 2013;5(1):43-47. PMID: 24155577, PMCID: PMC3768082
15. Msagati F, Simon EN, Owibingire S. Pattern of occurrence and treatment and treatment of impacted teeth at the

- Muhimbili National Hospital, Dar es Salaam, Tanzania. BMC Oral Health. 2013;13:37.
16. Tantanapornkul W, Okouchi K, Fujiwara Y, Yamashiro M, Maruoka Y, Ohbayashi N, et al. A comparative study of cone-beam computed tomography and conventional panoramic radiography in assessing the topographic relationship between the mandibular canal and impacted third molars. Oral Surg Oral Med Oral Pathol Oral Radiol Endod. 2007;103(2):253-9. PMID: 17234544, DOI: 10.1016/j.tripleo.2006.06.060
  17. Momin MA, Matsumoto K, Ejima K, Asami R, Kawai T, Arai Y et al. Correlation of mandibular impacted tooth and bone morphology determined by cone beam computed topography on a premise of third molar operation. Surg Radiol Anat. 2013;35(4):311–8. PMID: 23143074, DOI: 10.1007/s00276-012-1031-y
  18. Kursun S, Hakan KM, Bengi O. Use of cone beam computed tomography to determine the accuracy of panoramic radiographic markers: A pilot study. Journal of Dental Sciences. 2015;10(2):167-171. DOI: dx.doi.org/10.1016/j.jds.2013.04.003
  19. Nasser A, Altamimi A, Alomar A, AlOtaibi N. Correlation of panoramic radiograph and CBCT findings in assessment of relationship between impacted mandibular third molars and mandibular canal in Saudi population. Dent Oral Craniofac Re. 2018;4(4):1-5. [DOI: 10.15761/DOCR.1000256]
  20. Khan I, Halli R, Gadre P, Gadre KS. Correlation of Panoramic Radiographs and Spiral CT Scan in the Preoperative Assessment of Intimacy of the Inferior Alveolar Canal to Impacted Mandibular Third Molars. J Craniofac Surg. 2011;22(2):566-70. PMID: 21403569, DOI: 10.1097/SCS.0b013e3182077ac4
  21. Blaeser BF, August MA, Donoff RB, Kaban LB, Dodson TB. Panoramic Radiographic Risk Factors for Inferior Alveolar Nerve Injury After Third Molar Extraction. J Oral Maxillofac Surg. 2003; 61:417-21. [PMID: 12684956, DOI: 10.1053/joms.2003.50088]
  22. Monaco G, Montevecchid M, Bonettim GA, Gatto MRA, Checchi L. Reliability of panoramic radiography in evaluating the topographic relationship between the mandibular canal and impacted third molars. J Am Dent Assoc. 2004;135(3):312-8. [PMID: 15058618, DOI: 10.14219/jada.archive.2004.0179]
  23. Nakayama K, Nonoyama M, Takaki Y, Kagawa T, Yuasa K, Izumi K et al. Assessment of the relationship between impacted mandibular third molars and inferior alveolar nerve with dental 3-dimensional computed tomography. J Oral Maxillofac Surg. 2009;67(12):2587-91. PMID: 19925976, DOI: 10.1016/j.joms.2009.07.017
  24. Jhamb A, Dolas RS, Pandilwar PK, Mohanty S. Comparative Efficacy of Spiral Computed Tomography and Orthopantomography in Preoperative Detection of Relation of Inferior Alveolar Neurovascular Bundle to the Impacted Mandibular Third Molar. J Oral Maxillofac Surg. 2009;67(1):58-66. PMID: 19070749, DOI: 10.1016/j.joms.2008.06.014
  25. Sedaghatfar M, August MA, Dodson TB. Panoramic radiographic findings as predictors of inferior alveolar nerve exposure following third molar extraction. J Oral Maxillofac Surg. 2005;63(1):3-7. PMID: 15635549, DOI: 10.1016/j.joms.2004.05.217
  26. Ghaemina H, Meijer GJ, Soehardi A, Borstlap WA, Mulder J, Berge SJ. 'Position of the impacted third molar in relation to the mandibular canal. Diagnostic accuracy of cone beam computed tomography compared with panoramic radiography. Int J Oral Maxillofac Surg. 2009;38(9):964-71. PMID: 19640685, DOI:10.1016/j.ijom.2009.06.007

© 2021 Herath et al.; This is an Open Access article distributed under the terms of the Creative Commons Attribution License (<http://creativecommons.org/licenses/by/4.0>), which permits unrestricted use, distribution, and reproduction in any medium, provided the original work is properly cited.

Peer-review history:  
The peer review history for this paper can be accessed here:  
<http://www.sdiarticle4.com/review-history/64929>