



Case Report of Ring Chromosome 13: 46,XX,r(13)(p13q34)/46,XX,dic r(13;13)(p13q34;p13q34)

Maurício Assis Rodrigues^{1*}, Renata Vasconcelos Moreira¹
and Patrícia Damasceno Ribeiro^{1*}

¹XY Diagnose Biotechnology Laboratory Ltda, Campos dos Goytacazes, RJ, Brazil.

Authors' contributions

This work was carried out in collaboration between all authors. Author MAR designed the study, cytogenetic analysis and interpretation of data and wrote the first manuscript. Author RVM contributed to research design and managed the literature searches. Author PDR contributed to the data management, provided advice for the study design and supervised the manuscript redaction. All authors read and approved the final manuscript.

Article Information

DOI:10.9734/BJMMR/2015/11666

Editor(s):

(1) Sinan INCE, Department of Pharmacology and Toxicology, University of Afyon Kocatepe, Turkey.

Reviewers:

(1) Anonymous, Michigan State University, USA.

(2) Anonymous, MGM Institute of Health Sciences, India.

(3) Anonymous, National Centre for Medical Genetics, Cuba.

(4) Anonymous, University of Colombo, Sri Lanka.

Peer review History: <http://www.sciencedomain.org/review-history.php?iid=644&id=12&aid=5960>

Case Study

Received 27th May 2014
Accepted 22nd July 2014
Published 5th September 2014

ABSTRACT

Aims: To report a case of ring chromosome 13 in a female child.

Presentation of Case: Female, Caucasian, born in Southeast of Brazil, 6 years old. Born by cesarean section, the physical examination at 6 years and 1 month old has shown: weight of 19.100 grams and 105 centimeters tall, developmental delay, bushy eyebrows, epicanthic folds and broad nasal bridge, cardiovascular and respiratory systems were normal and no abnormalities in the limbs. Chromosome analysis was performed by GTG banding of peripheral blood and the karyotype was 46,XX,r(13)(p13q34)[97]/46,XX,dic r(13;13)(p13q34;p13q34) [3]. Analysis of 100 metaphases following G-banding revealed 97% cells with a ring chromosome 13,3% with dicentric ring chromosome of two 13s. Aneuploidy was not detected. Her parents had a normal karyotype.

Discussion: Some researchers relate the clinical presentation of ring chromosome 13 with the extension of the deleted chromosomal region and instability. Others suggested that phenotypes of

*Corresponding author: Email: pd_ribeiro@yahoo.com.br;

patients can be categorized in groups, according to the breakpoint on 13q.

Conclusion: The classification of cases in groups based on breakpoints and chromosomal instability is still inaccurate, with variable phenotypes. Thus, the analysis of a greater number of cases and molecular analysis are important to establish more precise correlation between genotype and phenotype.

Keywords: Ring chromosome 13; mental retardation; 13q deletion syndrome; chromosome abnormality.

1. INTRODUCTION

The ring chromosome 13 is a rare genetic condition. It was first described in 1968 by Lejeune et al. [1] with an estimated incidence of 1 in 58,000 live births. The familial transmission of this chromosome was described in 2004 by Bedoyan et al. [2]. Features of r(13) include intellectual disability, facial dysmorphisms, microcephaly, and hypertelorism [3].

Ring chromosomes have been reported for all chromosomes however those involving chromosomes 13 and 18 are among the most common [4]. When ring chromosomes replace a normal homolog in a karyotype, they often represent a partial monosomy for both long and short arm material. When rings are present as supernumerary chromosomes, partial trisomies are a result [5].

According to Bedoyan et al. [2] 99% of the formation of ring chromosomes occurs sporadically. Here the authors report a case of ring chromosome 13 in a female child and compare the findings with other reported cases with breakpoints at p13q34.

2. PRESENTATION OF CASE

Our patient was referred to the Center of Reference and Treatment of Children and Adolescents (Campos dos Goytacazes, RJ, Brazil) due to mental retardation and speech delay. At 5 years and 7 months age, she had difficulties in cognition and language. She can't recognize letters of the alphabet. The child was used to show interest in school cognitive activities, but concentration was difficult. She crawled at 9 months of age, walked at 1 year and 4 months and showed normal dentition at 10 months. Hearing and vision were normal and the child had good social interaction and a docile behavior.

The patient's parents were normal and non-consanguineous, and her older sibling was born a normal child. The first fetal movement was noticed at 3 months of pregnancy and the mother had suffered from gestational diabetes. The baby was born through cesarean section. Her weight and height were 2.910grams and 46cm, respectively.

The physical examination at 6 years and 1 month of age revealed: weight of 19.100 grams and 105 centimeters tall, growth retardation, mental retardation, facial dysmorphism, bushy eyebrows, epicanthic folds and broad nasal bridge, cardiovascular and respiratory systems were normal and there were not abnormalities in the limbs.

2.1 Cytogenetic Study

Routine chromosome preparations were made from peripheral blood lymphocytes after 72h in culture with RPMI-1640 supplemented with 20% fetal bovine serum and phytohemagglutinin (PHA). The G banding technique (400 bands) was applied to analyze cells from the patient and her parents. The chromosomes were classified according to ISCN (2013) [6].

Cytogenetic studies were performed according to standard methods described by Verma and Babu [7] and showed mosaic karyotype with 46,XX,r(13)(p13q34)[97]/46,XX,dic r(13;13)(p13q34;p13q34) [3]. The number of cells counted, karyotyped and analyzed were 100, 20 and 10, respectively, and revealed: 97% of the cells with 46,XX,r(13)(p13q34) karyotype and 3% with 46,XX,dic r(13,13)(p13q34;p13q34) pattern (Figs. 1A and 1B). No loss of any chromosomal band could be identified in the ring chromosome 13 at the 400- to 500-band level. The parents had a normal karyotype.

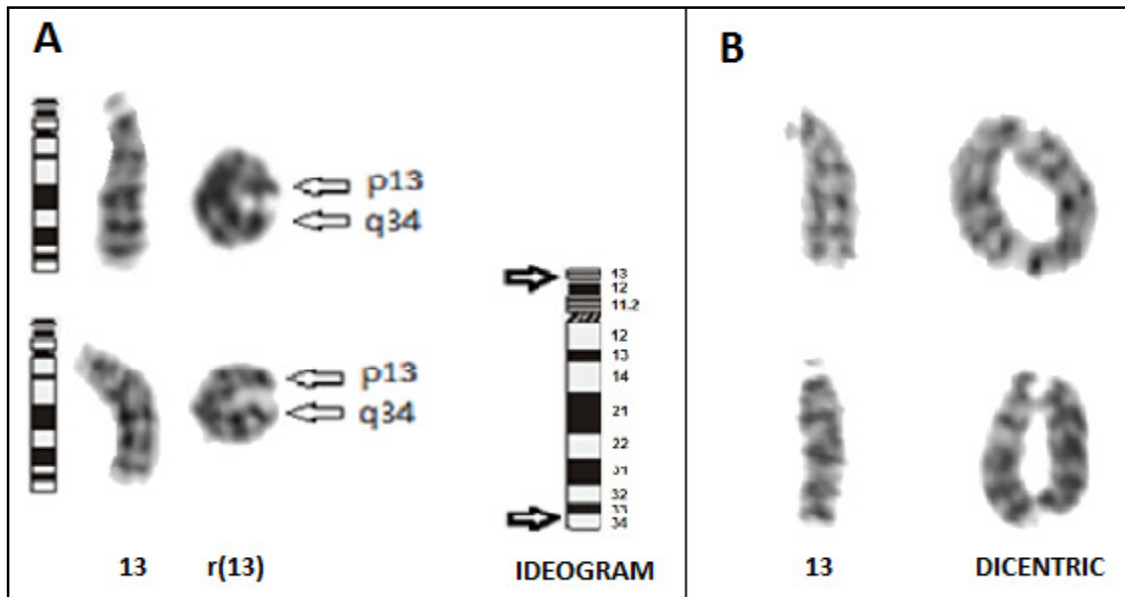


Fig. 1. Partial G-banded karyotype of the patient. A. The normal and the ring chromosome 13. B. The normal and the dicentric ring chromosome 13

3. DISCUSSION

In the present study we compare phenotypes of a patient with other reported cases in literature for r(13) with breakpoint in p13q34 (Table 1), previously described by Lowry and Dill [8], McCorquada et al. [9], Bedoyan et al. [10], Kim et al. [11], P. -Hu. Su et al. [3] and Ballarati et al. [12].

Our findings are consistent with those from literature and emphasize three pathognomonic features of ring chromosome 13 syndrome: mental retardation, developmental delay and facial dysmorphism. Descriptions as anomalies in upper and lower extremities were uncommon, whereas mental retardation was predominant, being present in all the cases described. The reported cases with the most severe phenotypes showed secondary chromosomal abnormalities (dicentric chromosomes or chromosomes in interconnected ring) and/or aneuploidy (hypoploidias, chromosome loss).

Secondary abnormalities were not seen in the case of Bedoyan et al. [2], and the only clinical feature described was mental retardation, which reinforces the hypothesis of the influence of instability on the phenotype of patients with the syndrome. Previous studies suggested that cells with secondary abnormalities would not be able to survive *in vivo* and would be eliminated in subsequent cell divisions [13].

Some authors relate the clinical presentation of “ring chromosome 13 syndrome” with the size of the ring chromosome and ring stability [14], while others did not find a correlation between r(13) and size of the ring chromosome and ring stability [15].

Based on clinical features, these deletions have been categorized into three groups [16]. Group 1 deletions comprise the chromosome region proximal to 13q32 and are characterized by mild to moderate mental retardation and variable facial dysmorphic features. Deletions of 13q32 (Group 2) are associated with the most severe phenotype, often including malformations of the brain, eyes, distal limbs, and the genitourinary and gastrointestinal tract. Patients with 13q32 deletions invariably have severe mental retardation and short stature. Distal deletions of bands 13q33–34 (Group 3) cause mental retardation, microcephaly, and genital malformations in males, but are normally not associated with other major malformations [12].

In a previous study performed by Kosztolányi [13], a ring chromosome was considered to be “stable” when secondary aberrations were found in 0-5% of the mitoses and “unstable” when such aberrations occurred in more than 5% of the mitoses counted.

Table 1. Comparison of clinical features of our patient with other r(13) cases

Clinical features	References						
	Lowry and Dill [8]	McCorquodale et al. [9]	Bedoyan et al. [10]	Kim et al. [11]	P.-H. Su et al. [3]	Ballarati et al. [12]	Present case
Sex (female/male)	M	F	F	M	F	F	F
Gestational age (week)	41	37	≥37	37	Full term	40	NI
Birth weight (g)	2350	2155	3090	1860	2060	3000	2910
Birth length (cm)	47	46	48	NI	44	NI	46
Maternal age (year)	23	17	18	28	25	NI	30
Microcephaly	+	+	-	+	+	-	-
Mental retardation	+	+	+	+	+	+	+
Growth retardation	+	+	+	+	+	+	+
Epicanthic folds	+	+	-	NI	+	-	+
Facial dysmorphism	+	+	-	+	+	NI	+
Broad nasal bridge	NI	NI	-	NI	+	-	+
Vision anomalies	NI	NI	-	NI	+	-	-
Hearing anomalies	NI	NI	-	NI	+	-	-
Hard palate	+	NI	NI	NI	NI	-	-
Hand anomalies	+	+	-	+	+	-	-
Foot anomalies	-	-	-	+	+	+	-
Finger anomalies	-	-	-	+	+	-	-
Skeletal abnormalities	-	-	-	-	+	+	-
Renal anomalies	NI	NI	-	-	+	NI	-
Hypertelorism	NI	+	-	+	+	+	-
Hipotonia	-	-	NI	+	NI	+	-
Heart defects	+	NI	NI	-	-	-	-
Genital malformations	-	-	NI	-	NI	-	-
Breakpoint	p13q34	p13q34	p13q34	p13q34	p13q34	q34-qter	p13q34
Counted cells	100	500	100	50	100	NI	100
45,-r(13) (%)	0	0-2	0	3	14	NI	0
46,r(13) (%)	95	96	100	44	82	NI	97
46,r(13) dicentric (%)	5	4	0	3	2	NI	3
Chromosome 13 mar (%)	0	0	0	0	2	NI	0

F, Female; M, Male; NI, No Information

The clinical case described here presented approximately 3% the cells with secondary chromosomal abnormalities, which according to this parameter, can be considered “stable”. Thus, the phenotype will actually depend on the size of the ring chromosome, the amount of euchromatin lost during ring formation, the ring stability, the presence of secondary aneuploid cells, and the rate of mosaicism [14]. However, studies of Sodr e et al. [4] concluded that the instability of ring chromosomes had not shown a clear relationship between ring size and its instability. Based on this study, we concluded that the ratio of mitotic stability related to clinical severity should be evaluated with caution.

4. CONCLUSION

The classification in groups through breakpoints and chromosomal stability is still inaccurate, with variable phenotypes. However, it is generally accepted that the severity of clinical cases is directly related to the amount of genetic material lost. Ring chromosomes with breaks in p13q34 are very rare and a few reports have been recorded so far. Thus, the analysis of a greater number of cases and molecular analyses of a greater number of cases are important to establish more precise correlation between genotype and phenotype.

CONSENT

All authors declare that ‘written informed consent was obtained from the parents of the patient for publication of this case report and accompanying images.

ETHICAL APPROVAL

All authors hereby declare that all experiments have been examined and approved by the appropriate ethics committee and have therefore been performed in accordance with the ethical standards laid down in the 1964 Declaration of Helsinki.

COMPETING INTERESTS

Authors have declared that no competing interests exist.

REFERENCES

1. Lejeune J, Lafourcade J, Berger R, Cruveiller J, Rethore MO, Dutrillaux B, Abonyi D, J r me H. The Dr phenotype: A study of three cases with a ring D chromosome. *Annals of Genetics*. 1968;11(2):79–87.
2. Bedoyan JK, Flore LA, Alkatib A, Ebrahim SA, Bawle EV. Transmission of ring chromosome 13 from a mother to daughter with both having a 46,XX,r(13)(p13q34) karyotype. *American Journal of Medical Genetics*. 2004;129A(3):316-320.
3. Su PH, Chen CP, Su YN, Chen SJ, Lin LL, Chen JY. Smallest critical region for microcephaly in a patient with mosaic ring chromosome 13. *Genetics and Molecular Research*. 2013;12(2):1311-1317.
4. Sodr e CP, Guilherme RS, Meloni VFA, Brunoni D, Juliano Y, Andrade JAD, Belangero SI, Christofolini, DM, Kulikowski LD, Melaragno MI. Ring chromosome instability evaluation in six patients with autosomal rings. *Genetics and Molecular Research*. 2010;9(1):134-143.
5. Gersen SL, Keagle MB. *The principles of clinical cytogenetics*. 2th ed. Humana Press: Totowa, New Jersey; 2005.
6. Shaffer LG, McGowan-Jordan J, Schmid M. *ISCN (2013): An International System for Human Cytogenetic Nomenclature*. Basel: Karger; 2013.
7. Verma RS, Babu A. *Human chromosome: Principles and techniques*. New York: Mc Graw Hill; 1995.
8. Lowry RB, Dill FJ. Ring 13 chromosome associated with microcephaly, congenital heart defect, intrauterine growth retardation, and abnormal skin pigmentation. *Birth Defects Original Article Series*. 1977;13(3B):216-21.
9. McCorquodale MM, Kolacki P, Kurczynski TW, Baugh E. Tissue-specific mosaicism for the stability of a ring 13 chromosome. *Journal of Mental Deficiency Research*. 1986;30(Pt 4):389-99.
10. Speevak MD, Smart C, Unwin L, Bell M, Farrell SA. Molecular characterization of an inherited ring (19) demonstrating ring opening. *American Journal of Medical Genetics, Part A*. 2003;121(2):141-145.
11. Kim SY, Oh SM, Kim MJ, Song ES, Kim YO, Choi YY, Woo YJ, Hwang TJ. A case of mosaic ring chromosome 13 syndrome. *Korean of Journal Pediatrics*. 2009;52(2):242-246.
12. Ballarati L, Rossi E, Bonati MT, Gimelli S, Maraschio P, Finelli P, Giglio S, Lapi E, Bedeschi MF, Gueneri S, Arrigo G,

- Patricelli, MG, Mattina T, Guzzardi O, Pecile V, Police A, Scarano G, Larizza L, Zuffardi O, Giardino D. 13q deletion and central nervous system anomalies: Further insights from karyotype-phenotype analyses of 14 patients. *Journal of Medical Genetics*. 2007;44(1):e60.
13. Kosztolányi G. Decreased cell viability of fibroblasts from two patients with a ring chromosome: An *In vitro* reflection of growth failure? *American Journal of Medical Genetics*. 1987;28(1):181-184.
14. Le Caigne C, Boceno M, Jacquemont S, Nguyen TTS, Rival JM, David A. Inherited ring chromosome 8 without loss of subtelomeric sequences. *Annales de Génétique*. 2004;47(3):289-296.
15. Kosztolányi G. Does “ring syndrome” exist? An analysis of 207 case reports on patients with a ring autosome. *Human Genetics*. 1987;75(2):174-179.
16. Brown S, Russo J, Chitayat D, Warburton D. The 13q syndrome: The molecular definition of a critical deletion region in band 13q32. *American Journal of Human Genetics*. 1995;57(4):859-66.

© 2015 Rodrigues et al.; This is an Open Access article distributed under the terms of the Creative Commons Attribution License (<http://creativecommons.org/licenses/by/4.0>), which permits unrestricted use, distribution, and reproduction in any medium, provided the original work is properly cited.

Peer-review history:

The peer review history for this paper can be accessed here:
<http://www.sciencedomain.org/review-history.php?iid=644&id=12&aid=5960>