



A Case Report of Pyrazinamide-Induced Hepatitis Complicated by Obstructive Hydrocephalus Secondary to Tubercular Meningitis in Pediatric Patient

**Latha Gowda Shamanur ^{a++}, Chandrasekhar Gouli ^{a#},
Jammula Mounika ^{b*} and Swathi M ^b**

^a Department of Pediatrics, SS Institute of Medical Sciences and Research Centre, Davangere-577004, Karnataka, India.

^b Department of Pharmacy Practice, Bapuji Pharmacy College, Shamanur Road, SS Layout, Davanagere - 577004, Karnataka, India.

Authors' contributions

This work was carried out in collaboration among all authors. Authors LGS and CG conceptualized the study. Author JM took the correspondence of the study and wrote the manuscript. Author SM prepared the original draft. All authors read and approved the final manuscript.

Article Information

Open Peer Review History:

This journal follows the Advanced Open Peer Review policy. Identity of the Reviewers, Editor(s) and additional Reviewers, peer review comments, different versions of the manuscript, comments of the editors, etc are available here: <https://www.sdiarticle5.com/review-history/114761>

Case Report

Received: 07/02/2024

Accepted: 11/04/2024

Published: 16/04/2024

ABSTRACT

This case report focuses on a pediatric patient with obstructive hydrocephalus secondary to tubercular meningitis, complicated by pyrazinamide-induced hepatitis. The elevated dosages of essential antituberculosis agents for pediatric use, recommended by the World Health Organization, raise concerns about heightened hepatotoxicity risk. Drug-induced liver injury (DILI) from anti-tuberculosis drugs is defined as hepatic injury, due to anti-tuberculosis drugs as

⁺⁺ Professor;

[#] Associate Professor;

^{*}Corresponding author: E-mail: mounikajammula99@gmail.com;

suggested by the international DILI Expert Working Group and American Thoracic society and recent evidence questions the safety profile of pyrazinamide compared to earlier perceptions. The main objective of our study was to identify the anti tubercular drug that caused hepatitis. The patient, a 10-month-old with a history of obstructive hydrocephalus due to TB meningitis, was started with anti tubercular therapy for which the baby was presented with yellowish discoloration of both eyes after 15 days of starting anti tubercular therapy. Clinical and diagnostic findings, including head to toe examination, Cerebrospinal fluid (CSF) analysis, neurosonogram, Contrast enhanced magnetic resonance imaging (CEMRI) of the brain, and abdominal ultrasound, were detailed. Laboratory investigations revealed abnormal liver function and increased inflammatory markers. Identification of pyrazinamide as the specific hepatotoxic agent was established through dechallenge and rechallenge assessments. The patient's management plan was modified to incorporate non-tubercular medications. Adjustments to the treatment regimen, including the discontinuation of pyrazinamide, were executed, resulting in an extension of isoniazid and rifampicin therapy for 9 months. The case highlights the need for a multidisciplinary approach, individualized treatment plans, and close monitoring in pediatric tuberculosis cases, particularly considering neurological and hepatic complications. Further research and awareness are crucial for refining treatment guidelines and improving overall care.

Keywords: Tubercular meningitis; pyrazinamide; drug induced liver injury; treatment regimen.

ABBREVIATIONS

DILI : Drug-Induced Liver Injury;
CSF : Cerebrospinal Fluid;
CEMRI : Contrast Enhanced Magnetic Resonance Imaging;
TBM : Tuberculous Meningitis;
INH : Isoniazid;
PZA : Pyrazinamide;
RMP : Rifampicin;
HIV : Human Immunodeficiency Virus;
BCG : Bacille Calmette-Guerin;
PCV : Packed Cell Volume;
LFT : Liver Function Test;
OD : Once Daily;
DIH : Drug-Induced Hepatitis.

1. INTRODUCTION

Tuberculous meningitis (TBM), recognized as the most devastating manifestation of tuberculosis, contributes to approximately 20% of childhood TB mortality [1]. The recent elevation in recommended dosages of essential antituberculosis agents, namely isoniazid (INH), rifampicin, and pyrazinamide (PZA), for pediatric use as advised by the World Health Organization has sparked concerns regarding the heightened risk of hepatotoxicity [2]. Anti-tuberculosis drug-induced liver injury (TB DILI), defined by the international DILI Expert Working Group and the American Thoracic Society, refers to hepatic injury resulting from the administration of anti-tuberculosis drugs [3].

PZA plays a crucial role as a cornerstone in the standard combination therapy for tuberculosis. Despite its indispensability, PZA is associated

with hepatotoxicity, and the exact mechanisms driving this adverse effect remain poorly elucidated. The prevailing notion implicating PZA's hepatotoxicity in its biotransformation within the liver emphasizes the intricate nature of its impact [4]. Initially perceived as a safer alternative compared to other potentially hepatotoxic anti-TB drugs like INH and rifampicin, recent Research has unveiled a reconsideration of PZA's safety profile. Contrary to prior beliefs, current evidence suggests that PZA might pose a higher risk of hepatotoxicity than previously understood, even surpassing the potential liver-related risks associated with both INH and rifampicin [4].

2. CASE STUDY

A 10-month-old female child, born to parents with 3rd-degree consanguinity, presented with a chief complaint of yellowish discoloration of both eyes

persisting for the last 3 days after starting the anti tubercular therapy. The patient had a history of obstructive hydrocephalus secondary to TB meningitis, diagnosed one month ago. Surgical interventions included the placement of a right ommaya reservoir followed by ventricular peritoneal shunting. The child was immunized up to date, with no BCG (Bacille Calmette-Guerin) scar observed. On examination, vital signs were within normal limits, and laboratory values indicated anemia and inflammation. Ultrasound

of the abdomen revealed cholelithiasis and mild hepatomegaly.

3. HISTORY OF ILLNESS

Two months prior, 8-month-old baby was admitted with insidious onset fever lasting for 8 days. Subsequently, the child developed a vacant stare, and difficulty recognizing individuals, and experienced recurrent fever and seizure episodes leading to readmission.

Table 1. Clinical status

Head-to-toe examination		
Head circumference	45cm (increased)	
General Status	Vacant stare look noted	
Neck Rigidity	Positive	
Anterior Fontanelle	Bulging	
Eyes	No sunset sign	
Head	Macrocephaly	
Extremities	Fisting of palm observed	
Motor System		
Tone	Increased in both upper and lower limbs	
Power	4/5 in both upper and lower limbs	
Reflexes	Exaggerated in both upper and lower limbs	
CSF analysis		
CSF glucose	18 mg/dl	Decreased
CSF protein	218 mg/dl	Increased
CSF chloride	120.5 mg/dl	Increased
Neurosonogram		
Impression - Bilateral lateral and 3rd ventricles were grossly dilated, causing a significant mass effect. Corpus callosum appeared compressed and thinned. Obstructive hydrocephalus, likely secondary to tubercular etiology.		
CEMRI of brain with seizure protocol		
Impression: Partial empty sella sign with torturous optic nerve and mild indentation of posterior sclera bilaterally. Leptomeningitis with severe obstructive hydrocephalus, likely of tubercular origin.		
Ultrasound of abdomen		
Cholelithiasis and mild hepatomegaly were noted.		

Table 2. Laboratory investigations

Laboratory Values		
C- reactive protein	38.20 mg/dl	Increased
Erythrocyte sedimentation rate	34 mm/hr	Increased
Hemoglobin	6.3 g/dl	Decreased
Red blood cells	2.7 million/cumm	Decreased
Packed cell volume (PCV)	20.1%	Decreased
Mean corpuscular volume	74.5 fl	Decreased
Mean corpuscular hemoglobin	23.2pg	Decreased
Total leucocyte count	34560 cells/cumm	Increased
Neutrophils	83%	Increased
Alkaline phosphatase	88.8U/L	Increased

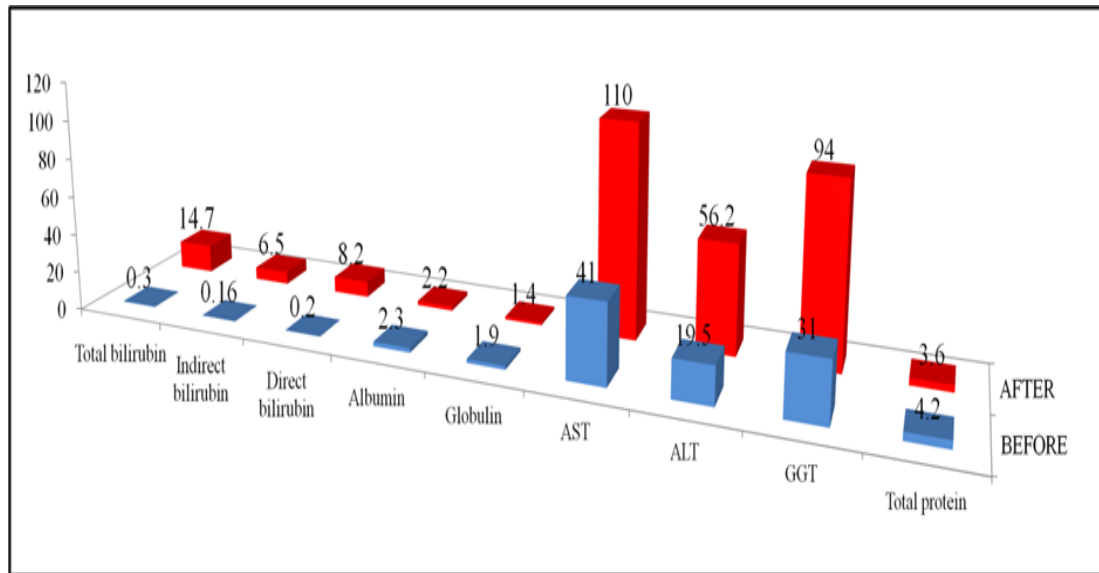


Fig. 1. Liver function test values before and after drug-induced hepatitis (DIH)

Table 3. Treatment regimen

Anti -TB Drugs	Before DIH		After DIH	
	Dose	Frequency	Dose	Frequency
Isoniazid	50 mg	1-0-0	100 mg	1-0-0
Rifampicin	75 mg	1-0-0	150 mg	1-0-0 (alternative day)
Pyrazinamide	150 mg	1-0-0	stopped	-
Ethambutol	100mg	1-0-0	stopped	-

4. DECHALLENGE AND RECHALLENGE ASSESSMENT

Upon diagnosing drug-induced hepatitis, the medical team decided to discontinue the anti-tubercular drugs to identify the specific agent responsible for hepatitis. Subsequently, the treatment plan was adjusted to incorporate non-tubercular medications, including Inj. Levofloxacin 80mg (10mg/kg/dose) 1-0-1, syrup prednisolone 5mg once daily (OD), and a PCV transfusion of 160ml over 4 hours. After 15 days icterus was resolved.

Later, a rechallenge was conducted with Isoniazid, and the infant was closely monitored for the presence of icterus and liver function test (LFT) abnormalities. Similar rechallenges were performed with Rifampicin and Pyrazinamide. Notably, there were no symptoms of icterus or LFT abnormalities observed with Isoniazid and Rifampicin. However, when Pyrazinamide was readministered, icterus and LFT abnormalities reappeared, confirming that Pyrazinamide was the specific drug responsible for the drug-induced liver injury. This dechallenge and

rechallenge process allowed for the precise identification of the hepatotoxic agent and informed the subsequent management of the patient's treatment plan.

5. DISCUSSION

Liver being metabolic factory of body is responsible for the drug metabolism and thereby more vulnerable to drug induced liver injury. All 3 essential first line anti-tubercular drugs (isoniazid, rifampicin and pyrazinamide) have the potential to cause liver injury with severity ranging between only liver enzymes level rise with no clinical symptomatology to overt hepatic failure [3]. Among the several detrimental consequences of anti-TB medications. Hepatotoxicity is a severe and crucial issue that affects both patients and clinicians. The interaction between regulatory bodies and drug developers can result in treatment disruptions, the development of drug resistance, severe liver harm, and potentially even death in patients with tuberculosis. The prevalence of anti-TB-DILI in the Indian population was 14.3% [5].

Highest percentage of patient developing TB DILI belongs to younger age group [3]. In children, small studies have reported rates of hepatotoxicity associated with TB treatment that varied from 8 to 40% although overall, the occurrence of drug-induced liver toxicity in children is considerably lower than in adults [6]. The hepatotoxic effects of anti-TB medications typically manifest within the initial 2 months of treatment, although they can occur at any point during the treatment duration [5]. Donald's review indicates that abnormal LFTs and jaundice were recorded in 53% and 10% of children, respectively, during treatment for TBM [7] Recent reports continue to confirm the relevance of hypoalbuminemia as a surrogate marker of malnutrition and a risk factor for TB DILI [8]. Amongst children approximately 10%, receiving either INH alone or INH accompanied by RMP or RMP and PZA, experience a rise in serum transaminase values or (in older studies) an abnormality in LFT [1]. In our study, pyrazinamide exhibited abnormal liver enzyme levels and icterus, indicating hepatic injury.

Usually diagnosis of TB DILI is based on suggestive clinical features in the presence of drug intake and their resolution with drug withdrawal [3]. The dechallenge and rechallenge process utilized in this case played a pivotal role in pinpointing pyrazinamide as the specific culprit behind the observed DILI. This approach facilitated the precise identification of the hepatotoxic agent in our study enabling the adjustment of the treatment plan to exclude the offending drug.

PZA hepatotoxicity is dose-dependent, especially at daily doses above 40 mg/kg, and the extent of PZA hepatotoxicity is correlated with its hepatic metabolism, suggesting a direct toxic effect, but not a hypersensitive or immune-mediated effect [2].

Conventionally, PZA is administered based on body weight (weight bands) both in children and adults. However, weight-based dosing may not be ideal for every patient owing to variability in drug exposure using this approach. Sex, human immunodeficiency virus (HIV) co-infection, and hepatic and renal impairment can contribute to variability in PZA pharmacokinetics. Furthermore, PZA is hepatically metabolised by microsomal deamidase to the active form pyrazinoic acid, which may differ between patients. Hence, patients may experience suboptimal treatment

response at lower PZA concentrations or toxicity at higher PZA concentrations [9].

Previous study by Shu et al demonstrated that the incidence of PZA-related DILI was 3.71 per 100 patient-month, which was more common than the incidence of INH- or RMP related DILI. Previous study demonstrated that those receiving a PZA-containing regimen had a higher risk of developing DILI [10] If DIH is attributed to pyrazinamide, it becomes necessary to discontinue pyrazinamide before completing the intensive phase, leading to an extension of isoniazid and rifampicin therapy to nine months which was made in our study as well. The strategic shift in managing the patient's condition involved the use of alternative non-tubercular medications, such as levofloxacin and prednisolone, along with a careful transfusion regimen. Thus follow-up requires screening for any hepatotoxicity besides general wellbeing of the patient helping in early detection and intervention that will reduce the risk of hepatic injury but also treatment failure [3].

6. CONCLUSION

This case report emphasizes the importance of a multidisciplinary approach in managing complex cases of tuberculosis in pediatric patients, taking into account both neurological and hepatic complications. It also underscores the significance of individualized treatment regimens and close monitoring to ensure optimal patient outcomes. Further research and awareness regarding the hepatotoxic potential of anti-tuberculosis drugs, especially pyrazinamide, is essential for refining treatment guidelines and improving the overall care of pediatric patients with tuberculosis.

CONSENT

As per international standards, parental written consent has been collected and preserved by the author(s).

ETHICAL APPROVAL

As per international standards or university standards written ethical approval has been collected and preserved by the author(s).

ACKNOWLEDGEMENT

We would like to express our sincere gratitude to our principal, HOD (Head of the department) and

all the professors of the department of pharmacy practice of Bapuji Pharmacy College, and the doctors of SS Institute of Medical Sciences and Research Centre who helped us in writing this case report.

COMPETING INTERESTS

Authors have declared that no competing interests exist.

REFERENCES

1. Donald PR. Antituberculosis drug-induced hepatotoxicity in children. *Pediatric reports*. 2011;3(2):e16.
2. Hussain Z, Zhu J, Ma X. Metabolism and hepatotoxicity of pyrazinamide, an antituberculosis drug. *Drug Metabolism and Disposition*. 2021;49(8): 679-82.
3. Sultan MA, Asim H. Anti-Tuberculosis Therapy induced liver injury in children. *Annals of Punjab Medical College (APMC)*. 2018;12(2):103-8.
4. Shah PR, Sajjan C, Mistry M. Antituberculosis drug induced hepatitis: A case-report. *Indian Journal of Pharmacy Practice*. 2022;15(2).
5. Kumar A, Singh M, Singhal KC, Bansal AK. Level of hepatic enzymes and serum zinc and copper at start of Anti-tubercular treatment (ATT) and a onset of hepatitis induced by ATT. *Journal of Pharmacovigilance & Drug Safety*. 2023;20(1):6-9.
6. Sanchez-Codez M, Hunt WG, Watson J, Mejias A. Hepatitis in children with tuberculosis: a case report and review of the literature. *BMC Pulmonary Medicine*. 2020;20:1-4.
7. Ruslami R, Gafar F, Yunivita V, Parwati I, Ganiem AR, Aarnoutse RE, Wilffert B, Alffenaar JW, Nataprawira HM. Pharmacokinetics and safety/tolerability of isoniazid, rifampicin and pyrazinamide in children and adolescents treated for tuberculous meningitis. *Archives of Disease in Childhood*. 2022;107(1):70-7.
8. Devarbhavi H. Antituberculous drug-induced liver injury: current perspective. *Tropical Gastroenterology*. 2011;32(3): 167-74.
9. Chen RH, Michael T, Kuhlin J, Schön T, Stocker S, Alffenaar JW. Is there a need to optimise pyrazinamide doses in patients with tuberculosis? A Systematic Review. *International Journal of Antimicrobial Agents*. 2023;106914.
10. Wang YC, Chen KH, Chen YL, Lin SW, Liu WD, Wang JT, Hung CC. Pyrazinamide related prolonged drug-induced liver injury: A case report. *Medicine*. 2022;101(39):e30955.

© Copyright (2024): Author(s). The licensee is the journal publisher. This is an Open Access article distributed under the terms of the Creative Commons Attribution License (<http://creativecommons.org/licenses/by/4.0>), which permits unrestricted use, distribution, and reproduction in any medium, provided the original work is properly cited.

Peer-review history:

The peer review history for this paper can be accessed here:
<https://www.sdiarticle5.com/review-history/114761>