



A Study of Histopathological Spectrum of Lesions in Cervix Biopsies in a Tertiary Care Hospital

K. S. Kerthi ^{a≡*} and Vimal Chander ^{b⊙}

^a Saveetha Medical College and Hospital, Thandalam, Chennai-602105, India.

^b Department of Pathology, Saveetha Medical College and Hospital, Thandalam, Chennai-602105, India.

Authors' contributions

This work was carried out in collaboration between both authors. Both authors read and approved the final manuscript.

Article Information

DOI: 10.9734/JPRI/2021/v33i64B35330

Open Peer Review History:

This journal follows the Advanced Open Peer Review policy. Identity of the Reviewers, Editor(s) and additional Reviewers, peer review comments, different versions of the manuscript, comments of the editors, etc are available here: <https://www.sdiarticle5.com/review-history/75838>

Original Research Article

Received 25 October 2021
Accepted 29 December 2021
Published 30 December 2021

ABSTRACT

Introduction: Uterine cervix is prone to numerous infections, inflammations and malignancy. cervical cancer is the most common cancer in women which may be detected early with the aid of doing screening examination.

Aim: This study was done to examine and analyze the histopathological lesions of cervix and to evaluate the frequency of these lesions, to understand the spectrum of various neoplastic and non-neoplastic cervical lesions and to study the incidence and frequency of various cervical lesions in different age groups so as to target them for various diagnoses, early detection and raising awareness.

Study Design: Retrospective cross-sectional study.

Place and Duration of Study: The study was conducted for a duration of 15 months from January 2019 to March 2020 retrospectively. Different types of pathological lesions in cervix were analyzed in the department of Pathology at Saveetha medical college.

Methodology: This study consists of a total of 534 cases, Patients' available clinical profile and the histopathologic diagnosis were noted from the registers and all cases of cervical biopsies over the above time period were included for this study. The diagnoses were then classified into non-neoplastic, pre-invasive and invasive lesions and statistical analysis was done using IBM SPSS statistical package version 23 and JASP statistical package version 0.13.1.

[≡] II Year MBBS Student;

[⊙] Professor;

*Corresponding author: E-mail: kskerthi@gmail.com;

Results: In this study, 534 cases are studied. The most common age group associated with the occurrence of cervical lesions were 41-50 years, among them the most common non-neoplastic lesion was chronic cervicitis and the most common malignant lesion observed was squamous cell carcinoma.

Conclusion: In this study, non-neoplastic lesions were more common as compared to neoplastic lesions, adding to that chronic cervicitis being the most common. Histopathological examination and tissue biopsy help in the early detection and diagnosis of malignant and premalignant conditions. These prognostic measures could help the patients to have better treatment options and can at times reduce the fatality rate.

Keywords: Cervical lesions; chronic cervicitis; squamous cell carcinoma; cervix.

1. INTRODUCTION

The uterine cervix is bounded above by internal os and below by external os. The mucosa lining of cervix differs from body of the uterus by the absence of a submucosa [1]. Anatomically the cervix is differentiated into the ectocervix and the endocervical canal. The ectocervix is covered by a mature squamous epithelium. The endocervix is lined by columnar epithelium, mucus-secreting epithelium. In this squamocolumnar junction, the epithelium is variable and changes with age and hormonal influence. The "transformation zone" that is where squamous and columnar meets predispose to highly susceptible infections with HPV and neoplasms [2]. Thus, this acts as a "gateway" for various infections, cervical precursor lesions, which affects the cervix [3]. The cervical lesions are characterized as nonneoplastic, preinvasive and invasive neoplastic lesions [4]. Several Bacterial, viral, protozoan and fungi microorganisms cause infective forms of acute and chronic cervicitis. Recent studies indicate that chronic granulomatous cervicitis, though rare, is mostly caused by tuberculosis [5,6]. HPV cervicitis predisposes to pre-invasive cervical intraepithelial neoplasia (CIN I, II, III) and eventually to invasive cervical carcinoma [5,7]. The various measures towards a proper diagnosis of the patient involve categorization, recognition and familiarization of the cervical non-neoplastic lesions with their histomorphologic findings [5]. This type of cervical lesion is due to a reduction in immunity and hormonal replacement therapy [8]. Cervical cytology, histopathological and colposcopic examination are some of the diagnostic utilities used for cervical lesions [9].

2. MATERIAL AND METHODS

This study consists of a total of 534 cases, collected retrospectively from the department of

Histopathology, Saveetha Medical College, Chennai over a period of 15 months from January 2019 to March 2020. Patients' available clinical profiles and the histopathologic diagnosis were noted from the registers and all cases of cervical biopsies over the above time period were included for this study. Scanty and autolyzed specimens were excluded from this study.

The diagnoses was then classified into non-neoplastic, pre-invasive and invasive lesions and statistical analysis was done using IBM SPSS statistical package version 23 and JASP statistical package version 0.13.1.

3. RESULTS AND DISCUSSION

3.1 Results

This study included a total of 534 cases, with ages ranging from 21 years to 95 years with a mean of 46.1 years and SD of 11.888 which showed a normal distribution [Fig. 1].

Of the 534 cases, 512 cases (95.89%) were non-neoplastic, 7 cases (1.3%) were precursor lesions, 15 cases (2.8%) were neoplastic of which 1 was benign (which is a leiomyomatous cervical polyp) and 14 were invasive malignancies [Table 1].

3.1.1 Distribution of cervical lesions in different age groups

The commonly affected age groups are 41-50 years 213 cases (39.89%); followed by 31-40years 122 cases (22.85%) and 51-60years 93 cases (17.42%).

3.1.2 Distribution of non-neoplastic lesions

In our present study, the most common lesion was chronic cervicitis which was common in 41-50 years age group individuals, comprising a total of 491 cases (91.95%).

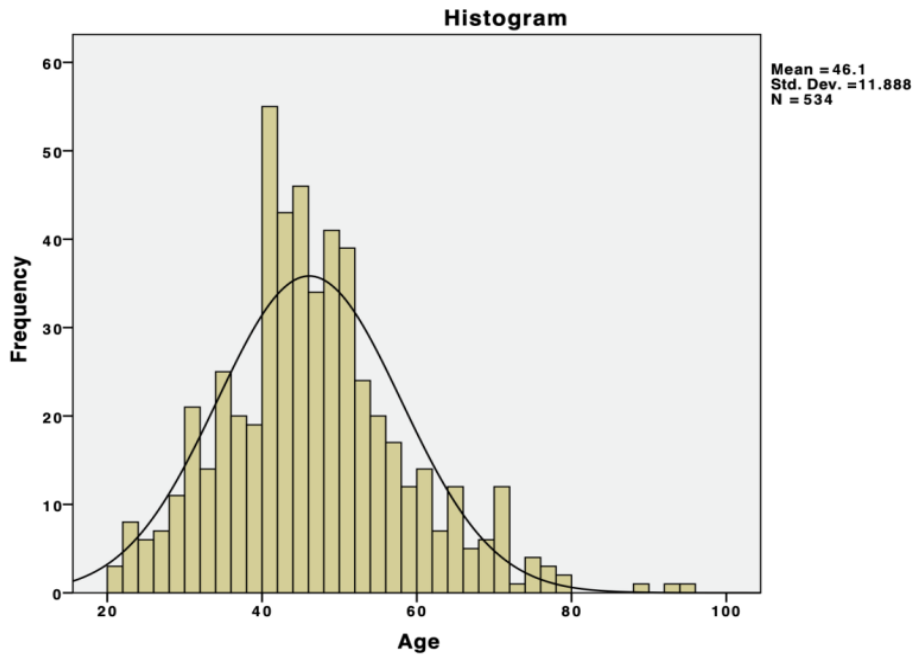


Fig. 1. Age distribution of cervix biopsy cases

Table 1. Distribution of cervix biopsy cases

	Frequency	Percentage
Nonneoplastic lesions	512	95.9 %
Benign neoplasms	1	0.2 %
Precursor lesions	7	1.3 %
Malignant neoplasms	14	2.6 %
Total	534	100 %

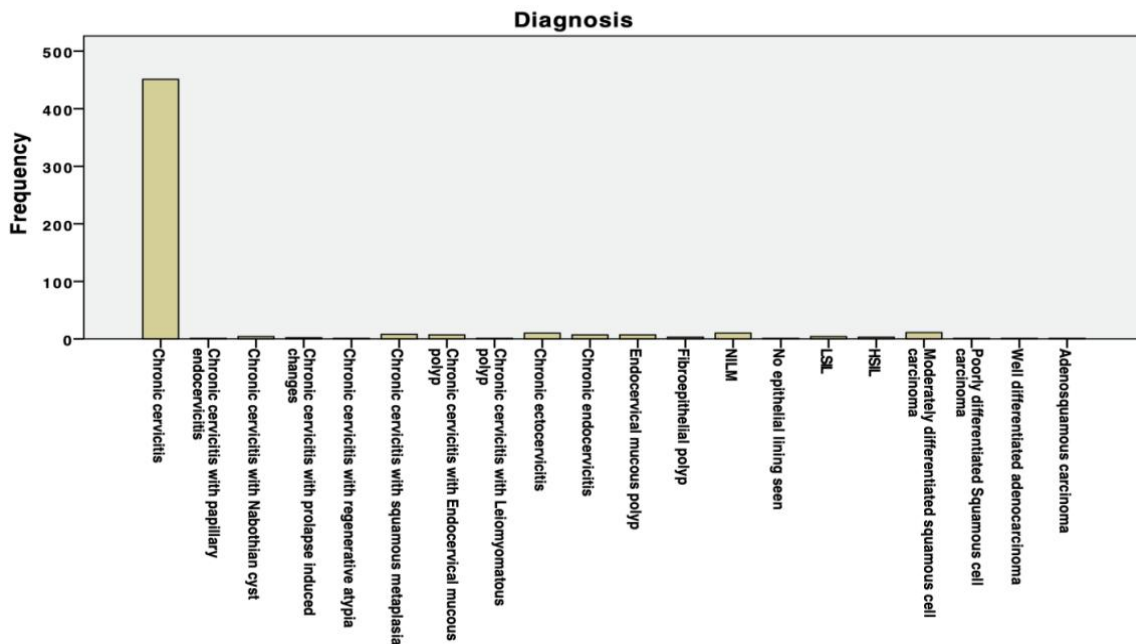


Fig. 2. Distribution of the total number of cervical biopsy cases

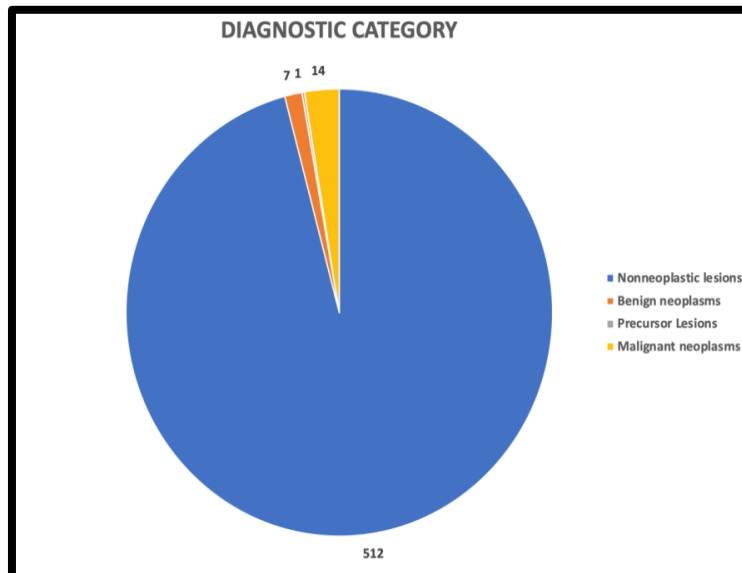


Fig. 3. Distribution of various cervical lesions

Table 2. Age wise distribution of cervical lesions

Age	Nonneoplastic (n)	Precursor lesions (n)	Benign neoplasm (n)	Malignant neoplasm (n)	Total (n)
21 – 30 years	48	0	0	0	48
31 – 40 years	121	0	0	1	122
41 – 50 years	199	6	1	7	213
51 – 60 years	89	1	0	3	93
61 – 70 years	39	0	0	2	41
71 – 80 years	13	0	0	1	14
81 – 90 years	1	0	0	0	1
91-100 years	2	0	0	0	2
Total	512	7	1	14	534

Table 3. Spectrum of lesions in cervix biopsies

Diagnostic category	Diagnosis	Frequency (n)	Percentage (%)
Nonneoplastic lesions	Chronic cervicitis	491	91.95
	Endocervical mucous polyp	7	1.31
	Fibroepithelial polyp	3	0.56
	NILM	10	1.87
	No epithelial lining seen, only stroma seen	1	0.19
Precursor Lesions	LSIL	4	0.75
	HSIL	3	0.56
Benign neoplasms	Chronic cervicitis with Leiomyomatous polyp	1	0.29
Malignant neoplasms	Moderately differentiated squamous cell carcinoma	11	2.06
	Poorly differentiated Squamous cell carcinoma	1	0.19
	Well differentiated adenocarcinoma	1	0.19
	Adenosquamous carcinoma	1	0.19

Table 4. Age wise distribution of various cervical lesions

Diagnostic category	Diagnosis	Age range (n)								Total
		21-30	31-40	41-50	51-60	61-70	71-80	81-90	91-100	
Non-neoplastic	Chronic cervicitis	45	104	176	78	32	13	1	2	451
	Chronic cervicitis with papillary endocervicitis	0	1	0	0	0	0	0	0	1
	Chronic cervicitis with Nabothian cyst	0	0	3	0	1	0	0	0	4
	Chronic cervicitis with prolapse induced changes	0	0	0	2	0	0	0	0	2
	Chronic cervicitis with regenerative atypia	0	0	1	0	0	0	0	0	1
	Chronic cervicitis with squamous metaplasia	0	2	3	1	2	0	0	0	8
	Chronic cervicitis with Endocervical mucous polyp	1	2	3	0	1	0	0	0	7
	Chronic ectocervicitis	0	4	2	2	2	0	0	0	10
	Chronic endocervicitis	0	2	4	1	0	0	0	0	7
	Endocervical mucous polyp	1	2	2	2	0	0	0	0	7
	Fibroepithelial polyp	0	2	1	0	0	0	0	0	3
	NILM	1	2	4	2	1	0	0	0	10
	No epithelial lining seen	0	0	0	1	0	0	0	0	1
	Total	48	121	199	89	39	13	1	2	512
Precursor lesions	LSIL			3	1					4
	HSIL			3	0					3
	Total			6	1					7
Benign neoplasm	Chronic cervicitis with Leiomyomatous polyp			1						1
	Total			1						1
Malignant neoplasm	Moderately differentiated squamous cell carcinoma		1	6	3	0	1			11
	Poorly differentiated Squamous cell carcinoma		0	0	0	1	0			1
	Well differentiated adenocarcinoma		0	0	0	1	0			1
	Adenosquamous carcinoma		0	1	0	0	0			1
	Total		1	7	3	2	1			14
Total		48	122	213	93	41	14	1	2	534

Table 5. Comparison of age-wise distribution of cases

	Saravanan et al. [10]	Pandit GA et al. [11]	Dubey K et al. [12]	Purushotham R et al. [13]	Our study
Age group	41-50 yrs (38.9%)	41-50 yrs (37.5%)	30-40 yrs (48.3%)	40-49 yrs (44.5%)	41-50yrs (39.89%)

Table 6. Comparison of frequency of cervical lesions with other studies

	Non-neoplastic	Preinvasive (LSIL and HSIL)	Invasive
Ali et al	46.34%	2.43%	51.2%
Kumari k et al.	49.39%	15.29%	35.31%
Bagde et al. [14]	46.51%	24.1%	13.95%
Fatima et al. [15]	35.33%	03%	61.66%
Jain et al. [16]	73%	23.5%	5.5
This study	96.07%	1.31%	2.63%

Cervical low-grade intraepithelial lesion (LSIL) was noted in 4 cases (0.75%), Cervical high-grade intraepithelial lesion (HSIL) was found in 3 cases (0.56%).

Squamous cell carcinoma (SCC) was the most common malignancy noted in 12 cases and Adenocarcinoma in 2 cases. Among SCC, moderately differentiated SCC in 11 cases, poorly differentiated SCC in 1 case.

Benign neoplasm included a case of Chronic cervicitis with Leiomyomatous polyp. Adenocarcinoma was seen in 2 cases, and the most affected age group in this malignancy was 41-50 years (8 cases).

3.2 Discussion

This study was conducted to study the histopathological spectrum of lesions in cervical biopsies and to assess its frequency in our hospital. A total of 534 cases were included in this study. Among them, non-neoplastic lesions were found to be more common. Chronic cervicitis was the most common lesion observed in this study. The most common age group involved was 41-50 years and the least number of cases were involved in the 81-90 year age group.

In our study, the age-wise distribution of cases was concordant with the study done by Saravanan et al. [10] and Pandit GA et al. [12].

This study consisted of 534 cervical biopsies. The maximum numbers of cases were of non-neoplastic lesions- 96.07%, this was concordant to the results of Jain et al and Kumari K et al in which non-neoplastic being the most 73% and

49.39% respectively. 14 cases were of invasive carcinoma comprising of Squamous cell carcinoma(13cases) and 2 cases of adenocarcinoma. Only 0.75% cases were LSIL, in which the normal epithelium could be brought back with treatment, 0.56% cases were diagnosed as HSIL.

4. CONCLUSION

The main objective of our study was to know the histopathological spectrum of cervical diseases and their frequency in our hospital. In our study, non-neoplastic lesions were more common as compared to neoplastic lesions, adding to that chronic cervicitis being the most common Histopathological examination, tissue biopsy helps in the early detection, diagnosis of malignant and premalignant conditions. These prognostic measures could help the patients to have better treatment options and can at times reduce the fatality rate.

DISCLAIMER

The products used for this research are commonly and predominantly use products in our area of research and country. There is absolutely no conflict of interest between the authors and producers of the products because we do not intend to use these products as an avenue for any litigation but for the advancement of knowledge. Also, the research was not funded by the producing company rather it was funded by the personal efforts of the authors.

CONSENT

It is not applicable.

ETHICAL APPROVAL

As per international standard or university standard written ethical approval has been collected and preserved by the author(s).

COMPETING INTERESTS

Authors have declared that no competing interests exist.

REFERENCES

1. Shaw W, Howkins J, Hudson CN. Shaw's Textbook of operative gynaecology. Edinburgh, Churchill Livingstone; 1977.
2. Harvard (18th ed.) Kumar V, Abbas AK, Fausto N, Robbins SL, Cotran RS. Robbins and Cotran pathologic basis of disease. Philadelphia, Elsevier Saunders; 2005.
3. Saini S, Kanetkar SR. Histopathological study of lesions of uterine cervix. J Evid. Based Med. Healthc. 2016;3(103):2349-2562
4. Omoniyi-Esan OG, Osasan SA, Ojo OS. Non-neoplastic diseases of the cervix in Nigeria: A histopathological study. Afr Health Sci 2006;6:76-80.
5. Reddy SD, Rani MS, Rao KS. Clinico-histopathologic study of nonneoplastic uterine cervical lesions. Int J Med Sci Public Health. 2016;5(8);1536-1539.
6. Zur Hausen H. Papillomaviruses and cancer: From basic studies to clinical application. Nat Rev Cancer 2002;2(5): 342.
7. Bosch FX, Lorincz A, Munoz N, Meijer CJ, Shah KV. The causal relation between human papillomavirus and cervical cancer. J Clin Pathol. 2002;55(4):244–65.
8. Priyadarshini D, Arathi CA. Histopathological spectrum of non-neoplastic uterine cervical lesions in a tertiary care centre. Annals of Pathology and Laboratory Medicine, [S.l.]. 2017;4(3): A303-309. ISSN 2349-6983
9. Bangera IS. Histopathological study of uterine cervix. International Journal of Science and Research. 2015;6(6):1183-1185.
10. Saravanan S, Arnold J, Arul P. Histomorphological spectrum of lesions of the cervix, A retrospective study in a tertiary care hospital. Journal of Evolution of Medical and Dental Sciences. 2015; 4(59):103326-10329.
11. Pandit GA, Khiste JA, Jindal S. Study of histomorphological spectrum of lesions of uterine cervix. International Journal of Current Research. 2016;8(5):30724-30727.
12. Dubey K, Garewal J, Naveen Kumar N, Sharma R, Arpita. Histopathological study of non neoplastic lesion in cervix at tertiary center. International Journal of Medical Research & Health Sciences. 2016;5(2):42-49.
13. Purushotham R, Sumaya, Nagesha KR. Histopathological spectrum of lesions of cervix. International Journal of Clinical and Diagnostic Pathology. 2019;2(1):306-310. DOI:<https://doi.org/10.33545/pathol.2019.v2.i1e.45>
14. Bagde S, Gupta R, Ganguly S, Bhardwaj A, Jogi S. Spectrum of cervical lesions in CIMS, Bilaspur: A 5 year retrospective study of 215 cases in a Tertiary Hospital of Central India. Journal of Evidence based Medicine and Healthcare. 2015;2(42): 7505-7510.
15. Fatima Q, Verma S, Bairwa NK, Gauri LA. Spectrum of various lesions in cervical biopsies in North West Rajasthan: A prospective histopathological study. Int J Med Res Prof. 2017;3(1):104-11.
16. Jain A, Dhar R, Patro P et.al. Histopathological study of cervical lesions. Int J Health Sci Res. 2018;8(11):82-87.

© 2021 Kerthi and Chander; This is an Open Access article distributed under the terms of the Creative Commons Attribution License (<http://creativecommons.org/licenses/by/4.0>), which permits unrestricted use, distribution, and reproduction in any medium, provided the original work is properly cited.

Peer-review history:

The peer review history for this paper can be accessed here:
<https://www.sdiarticle5.com/review-history/75838>