



## Small-bore Single Laparoscopy-assisted Trans-vaginal Ovarian Cystectomy for Benign Ovarian Diseases

Young-Sam Choi<sup>1\*</sup>, Ji-No Park<sup>2</sup>, Yun-Sang Oh<sup>2</sup>, Geun-Soo Kim<sup>3</sup>, Tae-Eel Rhee<sup>4</sup>  
and Ho-Sun Choi<sup>2\*</sup>

<sup>1</sup>Department of Obstetrics and Gynecology, Her Women's Clinic, Kwang-Ju Metropolitan City, South Korea.

<sup>2</sup>Department of Obstetrics and Gynecology, Chonnam National University Hospital, Kwang-Ju Metropolitan City, South Korea.

<sup>3</sup>Department of Urogynecology, Chonnam National University Hospital, Kwang-Ju metropolitan City, South Korea.

<sup>4</sup>Department of General Surgery, Chonnam National University Hospital, Kwang-Ju Metropolitan City, South Korea.

### Authors' contributions

This work was carried out in collaboration between all authors. Author YSC designed the study, performed operations, wrote the protocol and wrote the first draft of the manuscript. Authors JNP, YSO, GSK and TER performed operations and author HSC managed the analyses of the study. All authors read and approved the final manuscript.

### Article Information

DOI: 10.9734/BJMMR/2015/12646

#### Editor(s):

(1) Philippe E. Spiess, Department of Genitourinary Oncology, Moffitt Cancer Center, USA and Department of Urology and Department of Oncologic Sciences (Joint Appointment), College of Medicine, University of South Florida, Tampa, FL, USA.

#### Reviewers:

(1) Fatima Mubarak, Radiology, Aga Khan University Hospital, Pakistan.

(2) Moamar Al-Jefout, Department of Obstetrics and Gynaecology, Mutah Medical Faculty, Jordan.

(3) Georgios Androutsopoulos, Department of Obstetrics - Gynecology, School of Medicine, University of Patras, Rio, Greece.

Peer review History: <http://www.sciencedomain.org/review-history.php?id=644&id=12&aid=5941>

Original Research Article

Received 11<sup>th</sup> July 2014  
Accepted 31<sup>st</sup> July 2014  
Published 5<sup>th</sup> September 2014

### ABSTRACT

**Aims:** To evaluate the feasibility of small-bore single laparoscopy-assisted trans-vaginal ovarian cystectomy.

**Study Designs:** A retrospective study was performed through a review of the medical records of women who had undergone laparoscopy-assisted trans-vaginal ovarian cystectomy for

\*Corresponding author: Email: [chs1949@jnu.ac.kr](mailto:chs1949@jnu.ac.kr), [yschoimd@yahoo.co.kr](mailto:yschoimd@yahoo.co.kr);

benign conditions.

**Place and Duration of Study:** Department of obstetrics & gynecology of Her women's clinic and Chonnam National University Hospital, Between January 2010 to January 2014.

**Methodology:** 148 women had undergone small-bore (3-5mm) single-port laparoscopy-assisted trans-vaginal ovarian cystectomy for benign adnexal mass. The technique consists of small bore single laparoscopic inspection phase, trans-vaginal operative phase, and laparoscopic checking phase. Age, parity, body mass index (BMI), bilaterality, dimensions of mass, location, total operative time, hemoglobin change, and complications were measured.

**Results:** 148 procedures were successfully completed without the need for extra-umbilical puncture. The mean±SD of total operative time and the largest dimension of the mass were 46.9±21.5min and 6.9±4.1cm, respectively. Spillage of cystic contents was minimal, and if it did occur, it was localized to the posterior cul-de-sac with no related complication. The median decline in the hemoglobin level from before surgery to postoperative day 1 was 1.7±0.8g/dL. The pathologic diagnoses were as follows: dermoid cyst, 82; endometriotic cyst, 31; corpus luteal cyst, 12; serous cystadenoma, 5; mucinous cystadenoma, 9; parovarian or paratubal cyst, 9.

The postoperative courses were uneventful in most patients, but four had a transient fever greater than 38°C and 8 women had small operation site hematoma. All of them recovered following conservative management.

**Conclusion:** We believe that small-bore single laparoscopy-assisted trans-vaginal ovarian cystectomy ensures the advantages of trans-vaginal surgery and the safety of the laparoscope.

*Keywords: Single-port; transvaginal cystectomy; dermoid cyst; ovarian cyst; laparoscopy.*

## 1. INTRODUCTION

Benign ovarian cysts are common disease in women of reproductive age, and various minimal invasive surgeries for them have been introduced. Among them, single-port laparoscopic surgery is an innovative advancement in terms of minimal invasiveness, but it needs special instruments and advanced laparoscopic skills [1]. However, there is a forgotten and useful route to the pelvic cavity that all women have. Indeed, the vagina is a fully attractive route for access to the pelvic cavity.

The trans-vaginal approach to the pelvic cavity offers several advantages, such as shorter operative time, shorter hospital stay, and no abdominal scar [2-7]. The trans-vaginal approach, however, has fatal disadvantages, such as a narrow operation field and limited information about pelvic pathologic conditions. Thus, technical difficulties and fear are the main factors why most gynecologists hesitate to perform this procedure [8-12].

Thus, we adopt the strategy of "See & Treat".

The weak points of trans-vaginal surgery can be overcome through laparoscopy assistance that is similar to laparoscopy-assisted vaginal hysterectomy [8-12]. Aiming at minimal invasive surgery, we used trans-umbilical small-bore single-port laparoscope [3-5mm] and made

maximum efforts to hide the incision by making it smaller and more to the inner side of the umbilical crater. We performed trans-vaginal ovarian cystectomy for benign adnexal mass after inspection through small-bore single-port laparoscope. In this way, we ensured the advantages of trans-vaginal surgery and the safety of the laparoscope.

We present our preliminary experiences on small-bore trans-umbilical single-port laparoscopy-assisted trans-vaginal ovarian cystectomy for benign adnexal masses.

## 2. MATERIALS AND METHODS

This retrospective study was performed through a review of the medical records of those who had undergone trans-vaginal ovarian cystectomy at the Her women's clinic and Chonnam National University Medical School.

The study was approved by the institutional review board.

From January 2010 to January 2014, 160 women underwent small-bore (3-5mm) single-port laparoscopy-assisted trans-vaginal ovarian cystectomy (S-LAVOC) for adnexal mass, the diameters of which were between 4cm and 25cm, and the radiologic and laboratory features of which were suggestive of benign diseases. Of these women, however, 12 women were

converted to total laparoscopic surgery, such as three-channel single-port or conventional multiport operation, because of cul-de-sac obliteration. Eventually, 148 women were enrolled in this study.

The preoperative and intraoperative exclusion criteria were as follows: complete posterior cul-de-sac obliteration, intact hymen, suggestion of malignancy, pregnancy, and post-hysterectomy state. Preoperative trans-vaginal pelvic ultrasonography was performed to evaluate the characteristics of the mass (location, dimensions, malignancy potential) for all patients. In some cases, pelvic CT or pelvic MRI and tumor markers were used to distinguish benign from malignant diseases. Age, parity, body mass index (BMI), bilaterality, dimensions of mass, location, total operative time, hemoglobin change, and complications were recorded. We used leukocytosis and fever as an indicator of infection. Fever was defined as body temperature greater than 38°C on two consecutive measurements 24h after surgery.

## 2.1 Operative Procedure

The schema of S-LAVOC are as follows:

- 1<sup>st</sup> step: Inspection through laparoscopy
- 2<sup>nd</sup> step: Operation through the vagina
- 3<sup>rd</sup> step: Checking through laparoscopy

As shown in Fig. 1, in the laparoscopic inspection phase, the operation starts with a trans-umbilical small-bore (3-5mm) single-port laparoscopy under general anesthesia in all cases. After partial eversion of the umbilicus, a curved skin incision of less than 5mm is performed at the inferior margin of the hidden umbilical crater. A Verres needle is penetrated into the peritoneal cavity through the skin incision site by direct puncture technique, and the peritoneal cavity is insufflated with carbon dioxide gas.

After sufficient insufflation, a small-bore trans-umbilical trocar is applied instead of a Verres needle by direct puncture technique. The abdominopelvic cavity is explored through a small-bore single-laparoscope without ancillary puncture, including the nature and location of mass, pelvic adhesion, mobility of adnexa, and accessibility of the posterior cul-de-sac. The most important checking point is the posterior cul-de-sac, because posterior cul-de-sac obliteration is troublesome and risky to culdotomy in the vaginal phase.

If the posterior cul-de-sac is accessible and the mass is of a benign nature, then the operation shifts to the vaginal phase.

In the vaginal operative phase, povidone-iodine solution is applied into the vagina for dressing, and a sterile surgical drape is sutured to the skin of both the buttocks and the posterior fourchette to cover up the anus and the perineum.

Culdotomy is performed by direct incision technique.

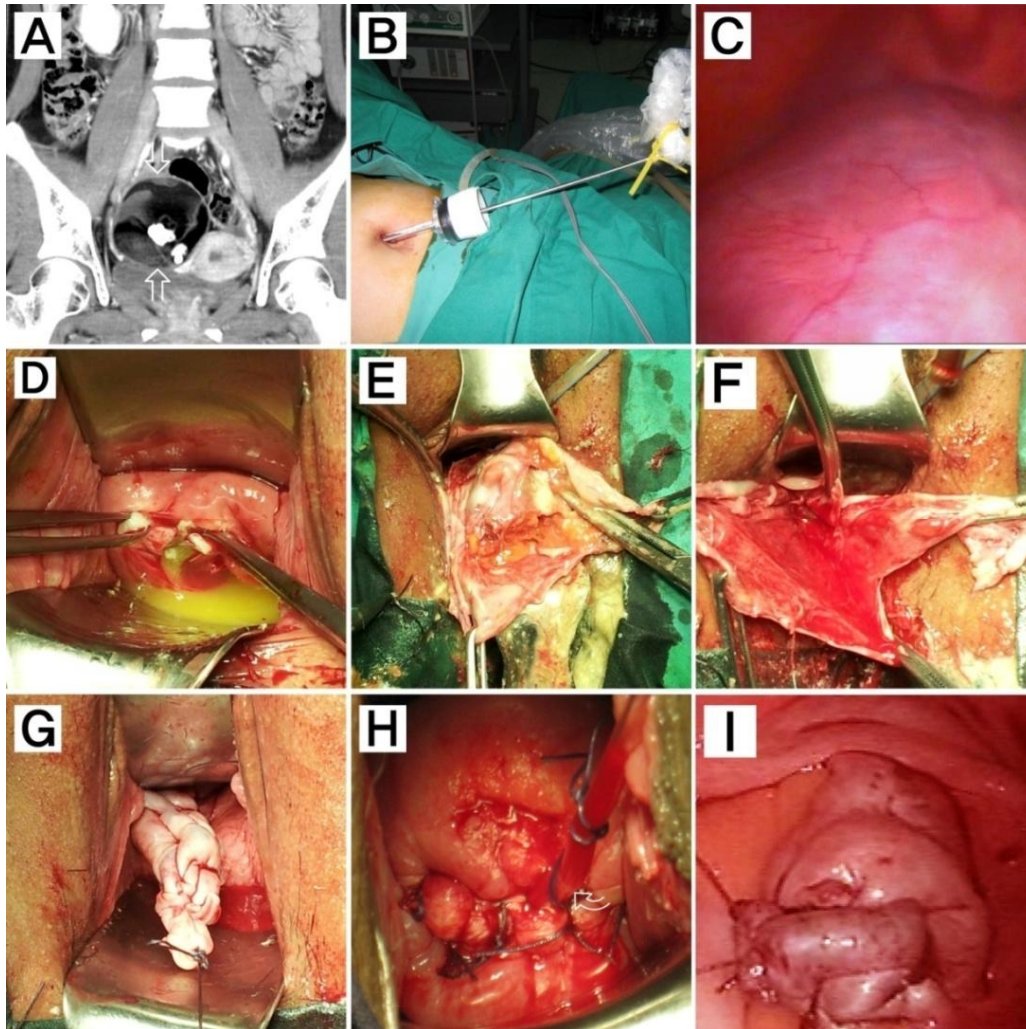
When the cyst is located within the Douglas pouch and can be accessed directly through the colpotomy opening, the cyst is caught and dragged down to the colpotomy opening with two Ellis forceps. A small incision is made on the cyst wall between the two Ellis forceps with tight adherence to the colpotomy opening, and the cystic opening is everted to the vagina to prevent spillage of cystic contents into the peritoneal cavity. The cystic contents are discharged and decompressed enough for partial exteriorization of the cyst.

The cyst wall is incised more widely, and solid contents are removed, such as hair, cartilage, and bone. The cyst is then enucleated extracorporeally, as like a conventional laparotomic cystectomy through the vagina. After cyst enucleation, the remnant healthy ovary can be exteriorized completely. The completely exteriorized ovary is inspected closely to check for other pathologic lesions and bleeding focus. The surgery site, vagina, and vulva are then irrigated sufficiently with sterile saline to clean out cystic contents and blood.

The remaining healthy ovarian tissue is repaired and returned to the original position, and sterile saline is poured into the abdominopelvic cavity through the trans-umbilical trocar. The poured fluid is drained through the vagina. Uterine movement, abdominal manual massage, and operation table tilting is useful for effective irrigation. In this manner, the peritoneal cavity is irrigated sufficiently to prevent chemical or infectious peritonitis. The canula for drainage is set from the pelvic cavity to the vagina, and the culdotomy site is repaired through the vagina. The operation then shifts to the laparoscopic checking phase.

In the laparoscopic checking phase, after intraperitoneal insufflation with carbon dioxide gas, the abdominopelvic cavity is checked,

including the operation site and pelvic cavity through trans-umbilical single laparoscope. The operation is complete after the checking phase.



**Fig. 1. Small-bore single laparoscopy-assisted trans-vaginal ovarian cystectomy (S-LAVOC) for an 8cm dermoid cyst arising from the right ovary (22-year-old woman)**

- A) Pelvic CT (coronary reconstruction view with contrast media enhancement): The image revealed a well-defined, multi-septated, spherical cystic mass of about 8 cm, with calcifications (open arrow). The findings correspond to a dermoid cyst.
- B) A small-bore (3-5mm) single-laparoscopy was applied through the umbilicus. We made maximum efforts to hide the incision by making it smaller and more to the inner side of the umbilical crater.
- C) Laparoscopic findings revealed a benign ovarian cyst arising from the right ovary without pelvic adhesion. The accessibility of the posterior cul-de-sac and the mobility of adnexa were checked.
- D) A small incision was made on the cyst wall with tight adherence to the colpotomy opening, and the cystic opening was everted to the vagina to prevent spillage of cystic contents into the peritoneal cavity.
- E) The cyst wall was incised more widely, and the cystic contents were removed.  
The cyst was enucleated through the vagina. If the cyst enucleation went well, the remnant healthy ovary could be exteriorized completely.
- F) The completely exteriorized ovary was inspected closely to checking for other pathologic lesions and bleeding focus. Later, the surgery site, vagina, and vulva were irrigated sufficiently with sterile saline to clean out cystic contents and blood.
- G) The remaining ovarian tissue was repaired. Sterile saline was poured into the abdomino-pelvic cavity through the trans-umbilical trocar and the poured fluid was drained through the vagina.
- H) The canula (curved open arrow) for drainage was set from the pelvic cavity to the vagina, and the culdotomy site was repaired.
- I) The abdominopelvic cavity was checked, including the operation site and the bleeding points through trans-umbilical single laparoscope

In the vaginal operative phase, it is essential to make the cyst visible directly and accessible from the vagina. For this, the adnexal mass should be prolapsed into the Douglas pouch as close as possible from the vagina. Regardless of cyst location and size, it is possible to move the cyst into Douglas pouch except for dense adhesion. Even if the cyst is located at the anterior or above the uterus, it is possible to drag it down into the Douglas pouch. For this reason, anterior colpotomy is not needed.

Cysts of about 6 to 8cm, especially dermoid cysts, are most ideal for this procedure. Dermoid cysts, because of that size and nature, have optimal mobility due to elongated hysteroovarian and infundibulopelvic ligament. Less ideal conditions require greater caution and more specific experiences and techniques. Endometriotic cysts have less mobility due to the nature of endometriosis despite the same size, and very small or huge cysts are not easy to drag down to direct access from the vagina.

When a cyst is too huge to descend within the Douglas pouch, but can be palpable with finger by an assistant's abdominal manual pressure, cystic contents are aspirated with a long puncture needle through the vagina. With palpation of the cyst using the index and the middle finger tips, a long aspiration needle is advanced to the cyst along the gap between the index and the middle fingers.

Great care should be taken to avoid bowel injury during advancement and puncture. Once cystic contents are discharged and decompressed a little, the cyst wall is wrinkled and can be caught with Ellis forceps. When cysts are too small to access and are far from the vagina, a laparoscopy assistant can drag down and access directly. Small cysts have limited mobility because the hysteroovarian and infundibulopelvic ligament is not elongated.

After intraperitoneal insufflation with carbon dioxide gas, a laparoscopic grasper forcep is inserted into the pelvic cavity through the culdotomy opening under laparoscopic inspection. The hysteroovarian ligament of the pathologic ovary is grasped with a laparoscopic grasper forcep and pulled down the ovary gently and the grip is switched with the Ellis forcep.

The next step is the same as the above-mentioned manners.

### 3. RESULTS

Among 160 patients, 148 procedures were successfully completed through this procedure without need for extra-umbilical puncture. 12 women who has posterior cul-de-sac obliteration and immobilization of cyst by dense adhesion could not complete the procedure; in these cases, the operation was converted to total laparoscopic surgery, such as single-port surgery using homemade three-channel single-port system or conventional multi-port surgery. Conversion to laparotomy never occurred in this series.

As shown in Table 1, patient age, parity, and BMI had mean±standard deviation (SD) values of 31.9±12.1 years, 1.0±1.2, and 22.5±4.0kg/m<sup>2</sup>, respectively. A total of 77 patients (52%) had no history of vaginal delivery; among them, 62 women were nulliparous and 15 had given birth by Caesarean section. A total of 30 patients (20.2%) had a past history of abdominopelvic surgery, such as a Caesarean section (10), repeat Caesarean section (5), laparoscopic tubal ligation (3), appendectomy (11), and salpingectomy (1). The mean±SD of total operative time and the largest dimension of the mass were 46.9±21.5min and 6.9±4.1cm, respectively.

Spillage of cystic contents was minimal. If it did occur, it was localized to the posterior cul-de-sac, with no related complication. There were no colpotomy-associated complications except for colpotomy site bleeding, which was controlled by simple compression.

The median decline in the hemoglobin level from before surgery to postoperative day 1 was 1.7±0.8g/dL, and white blood cell counts were doubled than before surgery in 30 patients (20.2%); for most of them, however, it was asymptomatic leukocytosis.

As shown in Fig. 2, LAVOC reveal excellent cosmetic outcome.

The pathologic diagnoses were as follows: dermoid cyst, 82; endometriotic cyst, 31; corpus luteal cyst, 12; serous cystadenoma, 5; mucinous cystadenoma, 9; parovarian or paratubal cyst, 9.

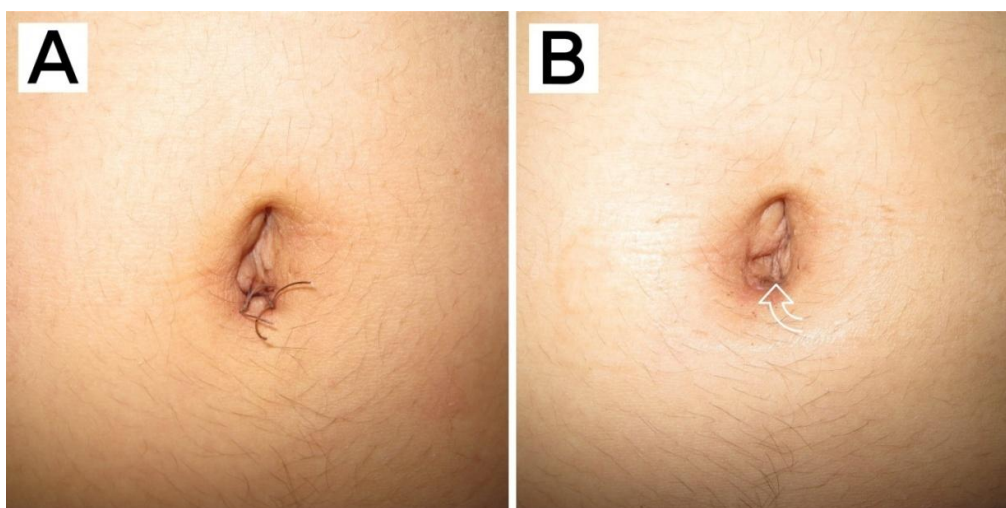
The postoperative courses were uneventful in most patients, but four women had a transient fever greater than 38°C and 8 woman had operation site hematoma. All of them were recovered following conservative managements.

**Table 1. Clinical data and surgical outcomes of trans-umbilical small-bore single laparoscopy-assisted trans-vaginal ovarian cystectomy (N=148)\***

	<b>Demographic characteristics</b>	<b>Median±SD**</b>	<b>Range***</b>	
Preoperative characteristics	Age (years)	31.9±12.1	14-48	
	Parity	1.0±1.2	0-4	
	Body Mass Index(kg/m <sup>2</sup> )	22.5±4.0	18.3-34	
	Nulliparity	62		
	Location			
	Right	79		
	Left	55		
	Both	14		
	Past abdominopelvic surgery	Caesarean section		10
		Repeat caesarean sections		5
		Tubal ligation		3
		Appendectomy		11
		Unilateral salpingectomy		1
		Indication for surgery (on pathologic report)	Dermoid cyst	
Endometriotic cyst			31	
Corpus luteal cyst			12	
Mucinous cystadenoma			7	
Serous cystadenoma			5	
Parovarian or paratubal cyst			9	
Intraoperative outcome	Total operative time (min)		46.9±21.5	30-200
	Largest dimension of mass (cm)	6.9±4.1	4-25	
	Extra-umbilical puncture	0		
	Conversion to laparotomy	0		
	Bowel injury	0		
	Spillage of cystic content	9		
	Blood transfusion	0		
Postoperative course	Hemoglobin drop (g/dL)	1.7±0.8	0.6-3.8	
	WBC doubling	30	Most asymptomatic	
	Febrile morbidity	4	Conservative management	
	Return to operation room	0		
	Transient paralytic ileus	3	Conservative management	
	Thromboembolic events	0		
	Operation site hematoma	8	Conservative management	
	Chemical or infectious peritonitis	0		
	Colpotomy-related complications	0		

\*:Among 160 patients, 12 patients were converted to total laparoscopic surgery due to posterior cul-de-sac obliteration. Eventually, 148 women were enrolled in this study. \*\*:Values are presented as mean ± standard deviation or absolute number\*\*\*: Values are presented absolute number or management





**Fig. 2. Photographs show postoperative intra-umbilical skin incision**

*A: Postoperative 3 days, B: Postoperative 2 weeks (curved open arrow indicates incision line)*

#### 4. DISCUSSION

As reported earlier, trans-vaginal ovarian cystectomy has several advantages and disadvantages compared with total laparoscopic cystectomy [2,8-14]. Although controversy remains, trans-vaginal ovarian cystectomy can be applied for huge ovarian cysts, involving shorter operative time, less cyst spillage, and favorable cosmetic outcomes [2-4,11-18]. In our series, cysts of more than 20cm in size were treated without any complications within 60 minutes.

Spillage of cystic contents has been a matter of grave concern in ovarian cystectomy, particularly where dermoid cysts are concerned. Although the implications of intraperitoneal spillage of cystic contents are controversial, the standard practice is to avoid the spillage of cystic contents [2,7,11-18].

In our series, spillage was rare. If it did occur, it involved a minimal amount and was localized to the posterior cul-de-sac because cysts were incised and drained to the vaginal cavity with eversion of the cystic opening to the vagina. Consequently, this can shorten the irrigation time. Further, we used a special lavage technique as described above. Due to the absence or the minimal amount of cystic contents spillage and the special lavage technique, the irrigation time was short, and it contributed to sparing operative time in this procedure. Short cyst enucleation and repair time are also associated with shortening of operative time.

Because of the anatomical feature of the lower genital tract, one theoretical complication of trans-vaginal surgery is the risk of pelvic infection. However, the theoretical infectious risk can be reduced by vaginal douche and a sterile surgical drape to cover up the perineum and the anus in a manner as suturing fixation to skin [2,19-22]. Remnant ovarian tissue, vagina, and vulva are irrigated with sterile saline extracorporeally before repair, to clean out cystic contents and prepare for potential infection risk.

In our series, four transient febrile episodes but all of them recovered following conservative management.

As described earlier, nulliparous women do not represent an absolute contraindication for trans-vaginal surgery [2]. In our series, trans-vaginal ovarian cystectomy was completed successfully in 62 nulliparous women and 15 women who had given birth by Caesarean section. However, women with intact hymen should be excluded to avoid hymenal injury. Hymen may have special meaning beyond mere anatomical structure, taking into account cultural considerations. Moreover, this procedure seems to be unsuitable for malignant lesions. Thus, preoperative evaluations are needed to exclude malignant lesions.

An essential step of this procedure is to secure direct exposure of the cysts for vision and access from the vagina. When cysts are immobilized or the posterior cul-de-sac is obliterated by adhesion secondary to endometriosis, previous

pelvic surgery, or pelvic inflammatory disease, trans-vaginal surgery is unsuitable.

However, endometriosis or previous pelvic surgery is not always adhesive. In our series, 31 cases with endometriomas and 30 cases who had previous pelvic surgery went through this technique. This was made possible due to laparoscopic inspection. In one case, the operative time was significantly long (200min) because the woman had a huge cyst (25cm) that contained, internally, a very hard, cortical long bone-like structures. The hard contents had to be fragmented with orthopedic surgical instruments. The operation was completed successfully without complications, which would have been impossible through total laparoscopic surgery.

More healthy ovarian tissue can be preserved through this procedure, because cyst enucleation is performed precisely along the exact cyst plane under direct vision, and hemostasis is performed by tie and suturing instead of electrocauterization.

We cannot conclude that our technique is superior to total laparoscopic surgery, because this study is not case-control study and the sample size is too small. However, more clinical experiences will reveal clearly the advantages and disadvantages.

## 5. CONCLUSION

We believe that trans-umbilical small-bore single laparoscopy-assisted trans-vaginal ovarian cystectomy ensures the advantages of trans-vaginal surgery and the safety of the laparoscope.

## CONSENT

All authors declare that 'written informed consent was obtained from the patient (or other approved parties) for publication of this article and accompanying images.

## ETHICAL APPROVAL

All authors hereby declare that all experiments have been examined and approved by the appropriate ethics committee and have therefore been performed in accordance with the ethical standards laid down in the 1964 Declaration of Helsinki.

## COMPETING INTERESTS

Authors have declared that no competing interests exist.

## REFERENCES

1. Uppal S, Frumovitz M, Escobar P, Ramirez PT. Laparoendoscopic single-site surgery in gynecology: Review of literature and available technology. *J Minim Invasive Gynecol.* 2011;18(1):12-23.
2. Kim JW, Kang WD, Kim KM, Kim SM, Oh ST, Choi HS, et al. Surgical treatment of ovarian dermoid cysts: A clinical evaluation between vaginal and laparoscopic removal. *Korean J Obstet Gynecol.* 2005;48(5):1241-8.
3. Massi GB, Savino L, Lena A, Susini T. Management of benign adnexal masses by vaginal route. *Front Biosci.* 1996;1:8-11.
4. Ferrari MM, Mezzopane R, Bulfoni A, Grijuela B, Carminati R, Ferrazzi E, et al. Surgical treatment of ovarian dermoid cysts: A comparison between laparoscopic and vaginal removal. *Eur J Obstet Gynecol Reprod Biol.* 2003;109(1):88-91.
5. Pillai R, Yoong W. Posterior colpotomy revisited: A forgotten route for retrieving larger benign ovarian lesions following laparoscopic excision. *Arch Gynecol Obstet.* 2010 ;281(4):609-11.
6. Ghezzi F, Raio L, Mueller MD, Gyr T, Buttarelli M, Franchi M. Vaginal extraction of pelvic masses following operative laparoscopy. *Surg Endosc.* 2002;16(12):1691-6.
7. Sheth SS. Management of ovarian dermoids without laparoscopy or laparotomy. *Eur J Obstet Gynecol Reprod Biol.* 2001;99(1):106-8.
8. Teng FY, Muzsnai D, Perez R, Mazdisnian F, Ross A, Sayre JW. A Comparative Study of Laparoscopy and Colpotomy for the Removal of Ovarian Dermoid Cysts. *Obstet Gynecol.* 1996;87(6):1009-13.
9. Tanaka M, Sagawa T, Mizumoto Y, Hashimoto M, Yoshimoto H, Yamazaki R, et al. Use of laparoscopic support to avoid laparotomy in vaginal ovarian cystectomy. *J Minim Invasive Gynecol.* 2008;15(3):350-4.
10. Pardi G, Carminati R, Ferrari MM, Ferrazzi E, Bulfoni G, Marcozzi S. Laparoscopically assisted vaginal removal of ovarian dermoid cysts. *Obstet Gynecol.* 1995;85(1):129-32.
11. Wang CJ, Chao A, Lai CH, Huang SY, Lee CL, Soong YK. Laparoscopically assisted vaginal ovarian cystectomy for clinically diagnosed benign large ovarian masses. *J*



- Laparoendosc Adv Surg Tech. 2009;19(5):623-8.
12. Wang CJ, Yen CF, Lee CL, Soong YK. Laparoscopic-assisted vaginal myomectomy. J Am Assoc Gynecol Laparosc. 2000;7(4):510-4.
  13. Tanaka M, Sagawa T, Yamazaki R, Myojo S, Dohi S, Inoue M. An alternative system for transvaginal removal of dermoid cyst and a comparative study with laparoscopy. SurgInnov. 2012;19(1):37-44.
  14. Göçmen A, Atak T, Uçar M, Sanlikal F. Laparoscopy-assisted cystectomy for large adnexal cysts. Arch Gynecol Obstet. 2009;279(1):17-22.
  15. Wang PH, Lee WL, Juang CM, Tsai WY, Chao HT, Yuan CC. Excision of mature teratoma using culdotomy, with and without laparoscopy: A prospective randomised trial. Br J Obstet & Gynaecol. 2001;108(1):91-4.
  16. Hessami SH, Kohanim B, Grazi RV. Laparoscopic excision of benign dermoid cysts with controlled intraoperative spillage. J Am Assoc Gynecol Laparosc. 1995;2(4):479-81.
  17. Kavallaris A, Mytas S, Chalvatzas N, Nikolettos N, Diedrich K, Bohlmann MK, et al. Seven years' experience in laparoscopic dissection of intact ovarian dermoid cysts. Acta Obstet Gynecol Scand. 2010;89(3):390-2.
  18. Remorgida V, Magnasco A, Pizzorno V, Anserini P. Four year experience in laparoscopic dissection of intact ovarian dermoid cysts. J Am Coll Surg. 1998;187(5):519-21.
  19. Neelam B, Derek T. Vaginal hysterectomy, reviews in gynaecological practice. 2004;4(2):82-8.
  20. Kantsevov SV. Infection prevention in NOTES. Gastrointest Endosc Clin N Am. 2008 ;18(2):291-6.
  21. Shackelford DP, Hoffman MK, Davies MF, Kaminski PF. Predictive value for infection of febrile morbidity after vaginal surgery. Obstet Gynecol. 1999;93(6):928-31.
  22. Bennett SJ, Waterstone JJ, Cheng WC, Parsons J. Complications of transvaginal ultrasound-directed follicle aspiration: A review of 2670 consecutive procedures. J Assist Reprod Genet. 1993;10(1):72-7.

© 2015 Choi et al.; This is an Open Access article distributed under the terms of the Creative Commons Attribution License (<http://creativecommons.org/licenses/by/4.0>), which permits unrestricted use, distribution, and reproduction in any medium, provided the original work is properly cited.

*Peer-review history:*

*The peer review history for this paper can be accessed here:*  
<http://www.sciencedomain.org/review-history.php?iid=644&id=12&aid=5941>